



Review Article

## The cerebellum in Autism

El cerebelo en el Autismo

Miguel Perez-Pouchoulen<sup>1,2</sup>, Marta Miquel<sup>3</sup>, Paul Saft<sup>1,2</sup>, Brenda Brug<sup>1,2</sup>, Rebeca Toledo<sup>1\*\*</sup>,  
Ma. Elena Hernandez<sup>1\*\*</sup>, Jorge Manzo<sup>1\*</sup>

<sup>1</sup>Centro de Investigaciones Cerebrales, Universidad Veracruzana, Xalapa, Ver., México <sup>2</sup>Doctorado en Neuroetología, Universidad Veracruzana, Xalapa, Ver., México <sup>3</sup>Area de Psicobiología, Universitat Jaume I, Castellón, España \*Cuerpo Académico de Neurociencias \*\*Cuerpo Académico de Neuroquímica.

Recibido: 07 de febrero de 2012

Aceptado: 31 de marzo de 2012

Puedes encontrar este artículo en: <http://www.uv.mx/eneurobiologia/vols/2012/5/5.html>

### Abstract

Autism is considered as a neurodevelopmental disorder which affects boys more than girls, in a proportion 4:1 respectively. Autism presents neuroanatomical abnormalities located in the frontal cortex, the amygdala and the cerebellum. Autistic cerebellar postmortem studies have revealed a reduced number of Purkinje cells as well as a reduced Purkinje cell size when compared with non-autistic subjects. These anatomical alterations compromise the role of the cerebellum in cognitive, motor, emotional, learning and memory neural processes resulting in a different interpretation of the world, and therefore a different way to respond and behave. There are both biological and environmental insults causing the behavioral and neuroanatomical autistic phenotype. Valproic acid, an antiepileptic drug, has been related to some autistic cases after mothers were under medication with this drug during the first trimester of gestation and given birth autistic children. Therefore, in this brief review we analyzed the most recent advances of autism research in humans, with a primary focus on the use of valproic acid as a teratogen that mimics in rats some of the neuroanatomical alterations seen in autistic humans. In addition to the peculiar cerebellar pathology, all of this to shed light on a better understanding of this disorder.

*Key words:* Autism, Purkinje neuron, Valproic acid, Teratogenicity.

### Resumen

El autismo es un trastorno generalizado del desarrollo que afecta más a varones que mujeres, con una proporción de 4 a 1, respectivamente. Dentro de sus características neuropatológicas más sobresalientes se encuentran la alteración anatómica de diversas estructuras del sistema nervioso central como la corteza frontal, la amígdala y el cerebelo. Estudios post mortem en cerebelos de sujetos autistas han mostrado una notable disminución en el número de neuronas de Purkinje así como en su tamaño, comparado con las de sujetos sanos. Estas alteraciones anatómicas comprometen la participación del cerebelo en los procesos neurales como la cognición, actividad motora, la emoción, el aprendizaje y la memoria, dando como resultado una interpretación diferente del mundo que impacta sobre la respuesta y el comportamiento de los sujetos autistas. Actualmente se desconoce la causa de estas alteraciones anatómicas y aunque se avanza rápido en la ciencia se tiene la limitante de los sujetos experimentales, que en este caso son humanos. Por lo tanto, en esta revisión analizamos los hallazgos más relevantes de la patología cerebelar en el autismo, así como el uso del ácido valproico en ratas como teratógeno para simular alteraciones cerebelares como las observadas en autistas, contribuyendo a un mejor entendimiento de su neuropatología.

*Palabras clave:* Autismo, Neurona de Purkinje, Ácido valproico, Teratógeno.

Correspondencia: M. en C. Miguel Pérez-Pouchoulén Centro de Investigaciones Cerebrales, Universidad Veracruzana Av. Dr. Luis Castelazo s/n, Col. Industrial Las Animas Xalapa, Ver. C.P. 91190 Teléfono: (228) 8418900 Ext. 13609 Fax: (228) 8418900 Ext. 13611 Correo electrónico: [miguel8329@gmail.com](mailto:miguel8329@gmail.com)

Este es un artículo de libre acceso distribuido bajo los términos de la licencia de Creative Commons, (<http://creativecommons.org/licenses/by-nc/3.0>), que permite el uso no comercial, distribución y reproducción en algún medio, siempre que la obra original sea debidamente citada.



## **Contents:**

1. Introduction
2. The cytoarchitecture of the cerebellum
3. Cerebellar abnormalities in autism
  - 3.1 *Abnormal cerebellar size*
  - 3.2 *Cerebellar neuronal abnormalities*
  - 3.3 *Cerebellar neurochemical alterations*
4. Valproic acid in rats: animal model for the study of autistic-like cerebellar alterations
5. Conclusions
6. Acknowledgements
7. References

## 1. Introduction

The world prevalence of the Autism Spectrum Disorder (ASD) has increased from 0.7/10000 to 72.6/10000 (1966-2003) and the male/female ratio of affection is 4:1, respectively.<sup>1</sup> The ASD involves different levels of alterations including the stereotypes and repetitive behavior, social interactions, communication and cognitive skills.<sup>2</sup> Insights into autism have come from neuroanatomical analysis using magnetic resonance (MR) and postmortem studies, which have revealed morphological alterations in several areas of the central nervous system (CNS) (e.g., the frontal cortex, the amygdala and the cerebellum).<sup>3-6</sup> Autistic brains show anatomical alterations in many areas of the limbic system including the hippocampus, the amygdala and the anterior cingulate gyrus, the septum as well as the prefrontal cortex and the cerebellum being the latter one of the most evident and commonly seen brain structure altered in autism. Originally, it was thought that the cerebellum participated only in motor skills; however, current research have shown the cerebellum to involve emotional processing, learning, memory, addiction, sexual reward, sexual behavior and communication.<sup>7-12</sup> Despite the advances in understanding the cerebellar physiology, its involvement in complex disorders such as autism, is poorly understood leaving a number of unresolved questions worthy of investigation. Hence, we reviewed here some of the most relevant findings about the cerebellar pathology related to autism, and to discuss the use of valproic acid (VPA) in rats as an animal model for the study of cerebellar abnormalities in autism.

## 2. The cytoarchitecture of the cerebellum

The cerebellum contains different type of cells that are homogeneously distributed in the entire cerebellar cortex. The most known cerebellar cells are the granule, stellate, basket, Golgi, Lugaro, unipolar brush and Purkinje neurons (Pkn) that all together constitute its neuronal circuitry and the

three different layers (molecular, Purkinje and granular) of the cortex. The stellate, basket, Lugaro, Golgi and Purkinje are inhibitory whereas granule and brush cells are excitatory neurons. It is important to know that the gamma-amino butyric acid (GABA) is the main inhibitory neurotransmitter in the cerebellum;<sup>13,14,15</sup> therefore the information processing requires an inhibition of the inhibition to allow sending the integrated information to the rest of the CNS. Also, the climbing and mossy fibers account for the excitatory inputs to the cerebellar cortex. The climbing fibers all come from the inferior olive and they form numerous synapses with the soma and dendrites of Pkn having a specific role during motor learning. Contrary, the mossy fibers mainly come from the vestibular and pontine nuclei establishing synapses with the granule cell dendrites.<sup>15</sup> Pkn is the only output of the cerebellar cortex as well as the biggest cerebellar neuron, its cell bodies forms the Purkinje layer that is located in the middle of the cortex, with a dendritic tree that spreads out over the molecular layer to receive synaptic inputs from the stellate and basket interneurons as well as from the excitatory parallel fibers.<sup>13,14</sup> The Pkn's axon descends through the granular layer until reach the cerebellar deep nuclei and then sends the information to the rest of the brain, mainly to the basal ganglia, midbrain, motor cortex and the spinal cord.<sup>16</sup> Based on the afferent connections to the cerebellum it can be subdivided in three main components: the vestibulocerebellum, the spinocerebellum and the cerebrocerebellum. The three components have specific functions and their afferent and efferent connections are from the same parts of the CNS. Thus, the vestibulocerebellum involves interactions between the vestibular nuclei and the flocculonodular lobe, the spinocerebellum involves connections between the anterior and posterior parts of the vermis and the spinal cord and the cerebrocerebellum implies connections between the cerebellar hemispheres and the cerebral cortex.<sup>15</sup> The same anatomical and functional divergence covers the deep

cerebellar nuclei. Now, the human cerebellum presents ten different lobules.<sup>17</sup> The rat cerebellum shows the same number of lobules<sup>8,9,18</sup> than the human cerebellum and it has been used as a model for the study of the cerebellar physiology. Interestingly,

although all the cerebellar lobules contain the same type of neurons (Figure 1) it has been shown that they respond differently to the same stimulus,<sup>8,10,11</sup> suggesting that each cerebellar lobule has a separate participation during cerebellar tasks.

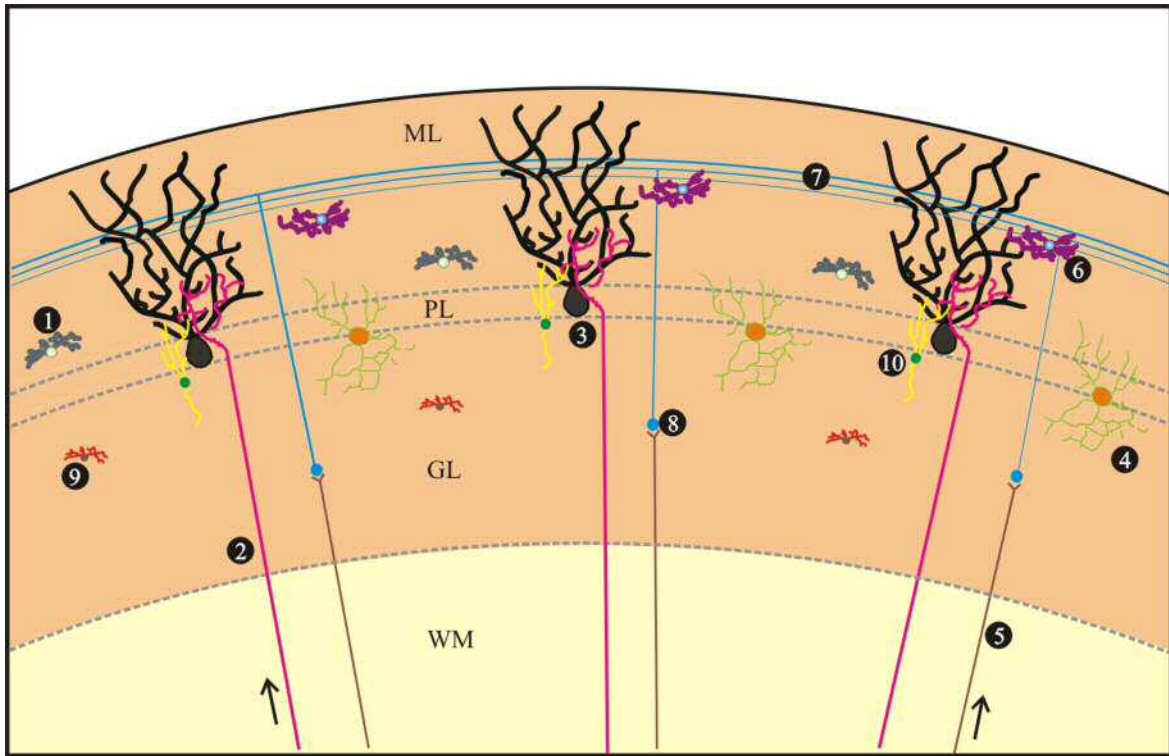


Figure 1. This drawing represents the cytoarchitecture of the cerebellum. Its cellular components are: 1. Basket cells. 2. Climbing fibers. 3. Purkinje neurons. 4. Golgi cells. 5. Mossy fibers. 6. Stellate cells. 7. Parallel fibers. 8. Granule cells. 9. Lugaro cells. 10. Brush cells. Also, it shows the three different layers of cerebellar cortex: molecular layer (ML), Purkinje layer (PL) and granule layer (GL), as well as the white matter (WM). Arrows points out the ascending directions of the climbing (left) and mossy fibers (right) coming from the inferior olive and the brain, respectively.

### 3. Cerebellar abnormalities in Autism

#### 3.1 Abnormal cerebellar size

The Magnetic Resonance Imaging (MRI) has been a helpful tool for the study of neuroanatomical alterations in autism. Nevertheless, the results obtained from this technique are heterogeneous, possibly due to

the complexity of this disorder. A study using 3-4 years old autistic children revealed an enlarged cerebral volume compared with their age-matched control and more interestingly, the cerebellar volume was increased in proportion to the total cerebral volume.<sup>5</sup> Furthermore, it has been reported that gray and white matter volumes were increased in autistic brains being the principal change in

both the cerebral and the cerebellar white matter.<sup>19</sup> Then it seems there was an unusual pattern of brain growth in these autistic brains which may be related to growth factors or even to the neuronal sprouting process that is essential during the first year of life in humans, to organize the neuronal nuclei and neural circuitries in the brain. In addition, a study found that the brain weight of autistic children comprising ages from 5 to 13 years old was 100 to 200 g heavier when comparing to controls. Opposite result was found in adult autistic subjects comprising ages from 18 to 54 years old who showed brains lighter than the controls,<sup>20</sup> which might indicate a degenerative process although this idea has to be determined. In contrast, a MRI study showed that children with autism spectrum disorder have reduced vermis volume as compared with their control, particularly the lobules VI to VII.<sup>21</sup> Then, hyperplasia or hypoplasia could be found in autism. This structural feature seems to vary with age,<sup>19,22</sup> although this trait is not unique of autism because other pathological conditions such as schizophrenia,<sup>23</sup> Sotos syndrome, fragile X syndrome and Cole-Hughes macrocephaly syndrome<sup>24</sup> also present abnormal head size and anomalies in specific brain areas involving limbic system and the cerebellum. More convincing data is needed in this field to continue in the pursuit of answers to telling us much more about the CNS, particularly the cerebellar development and its alterations.

### 3.2 Cerebellar neuronal abnormalities

The most relevant postmortem finding in the cerebellum of autistic individuals is a reduction in the number of Pkn in the posterior lobe of the vermis and hemispheres <sup>3,4,25-28</sup> which differs in number between young and adult autistic subjects, being the older ones the most damaged, suggesting a neurodegenerative process.<sup>3,4</sup> However, there is no report about abnormalities in the flocculonodular lobe of the autistic cerebellums. In addition, there is a variable decrease in the number of granule cells<sup>20</sup> but basket and stellate cells are preserved.<sup>29</sup> Moreover, other studies have revealed that Pkn size is smaller in autistic

cerebellums compared with their matched controls,<sup>30</sup> which might be related to some alterations of growth or neurotrophic factors which are involved in cell cycle, migration, cell differentiation and cell survival. Thus, any alteration on this set of cellular processes could be the responsible of Pkn abnormalities, modifying the integration of stimuli for a specific respond. Regarding the close relationship between Pkn and climbing fibers, it has been shown that there is a neuronal loss in the inferior olive of the autistic brainstem, an event that may occurs paralleling to the loss of Pkn in the cerebellum.

One idea suggests that during the prenatal development, the CNS is insulted and this phenomenon compromises its maturation, therefore altering timeframes of development impacting on the cerebellar development and maturation, which begins prenatally and ends postnatally, respectively. This premise is based on the fact that cerebellar neuronal loss is not accompanied by gliosis<sup>4</sup> indicating that the cerebellar damage occurs during the embryonic stage. As previously discussed, being Pkn the only cerebellar output either their reduced number or small size might change the information processing resulting in sending wrong signals to the rest of the brain, primarily to their first exchange information center, the deep cerebellar nuclei.<sup>15,16</sup>

In relation to the deep cerebellar nuclei (Figure 2) in the young autistic cerebellum, only the fastigial nucleus has shown a reduction in the number of neurons contrary to its neighbor nuclei.<sup>31</sup> However, in older autistic patients neurons were reduced in number in the fastigial, emboliform and globose nuclei.<sup>20</sup> Also, neurons in these cerebellar nuclei presented an enlarged size in autistic children whereas in adult subjects these neurons were smaller.<sup>4,20</sup> Therefore, disturbances in Pkn and deep cerebellar nuclei surely change the way that the cerebellum communicates with the brain, the brainstem and the spinal cord. Moreover, there is information about neurochemical alterations in these cerebellar nuclei which involves neurotransmitters such as serotonin and GABA as well as synaptic and apoptotic proteins.

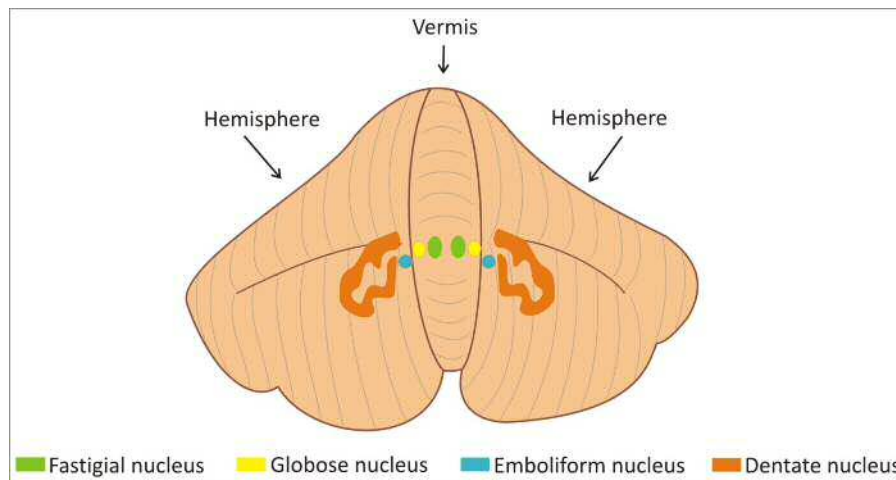


Figure 2. This human cerebellum design shows the location of the deep cerebellar nuclei in the vermis and hemispheres from the middle to the lateral side.

### 3.3 Cerebellar neurochemical alterations

This new field has progressed in the last 10 years and has produced interesting results. For example, expression of reelin, a protein that regulates neuronal migration in the early development and synaptic plasticity in the adulthood, and of Bcl-2, an apoptosis regulator protein, were reduced by 44% and 34% to 51% respectively, in the autistic cerebellum as compared with their matched sex, age and postmortem interval controls.<sup>32</sup> Reduction of reelin has been associated with reduced levels of brain-derived neurotrophic factor (BDNF).<sup>33</sup> Reelin is highly involved in the migration, a process that begins during gestation and ends months after birth, therefore any disturbance during this timeframe changes the normal cerebellar migration and the neuronal final location, compromising the way that neurons connect each other and certainly their physiology. In addition, glutamic acid decarboxylase (GAD) 65 kDa and 67 kDa expression are reduced one half in the autistic cerebellar cortex.<sup>34</sup> Specifically, both enzymes showed a reduced expression in Pkn but in basket cells were increased.<sup>35</sup> Additionally, only GAD65 is diminished in the dentate nucleus of autistic

cerebellums. Moreover, in autistic patients have been detected a mutation in the region that contains three GABA<sub>A</sub> receptor subunits ( $\alpha 5$ ,  $\beta 3$ ,  $\gamma 3$ ). It is known that GABA exerts trophic effects during the embryonic and perinatal development involving neuronal migration and neurite outgrowth.<sup>35</sup> There is a possibility that these GABAergic alterations may be involved in the cause of autism instead of being a consequence of it. Hence, being the cerebellum a structure that works mainly with GABA, this neurochemical alteration could affect dramatically the cerebellar networks and produce the behavioral phenotype of autistic subjects. Also, nicotinic  $\alpha 4$  receptor subunit is decreased whereas the  $\alpha 7$  subunit is increased.<sup>36</sup> It has been established that nicotinic receptors play an important role in synaptic and dendritic plasticity as well as synthesis of some neurotrophins such as nerve growth factor (NGF), BDNF and fibroblast growth factor (FGF-2) influencing the neuronal connectivity and transmission. At a different molecular stage, mRNA levels of the gene encoding for the excitatory amino acid transporter 1 and glutamate receptor AMPA 1 were significantly increased in the cerebellum of autistic individuals, whereas the AMPA-type glutamate density receptor was decreased.<sup>37</sup>

Serotonin concentration is also altered in autistic brains. Particularly, in the autistic cerebellum, the right deep dentate nucleus presents an increased concentration of serotonin whereas in the frontal lobe is decreased.<sup>38</sup> It is known that serotonin has trophic actions during brain development by regulating cell differentiation, neurite outgrowth and synaptogenesis.<sup>38</sup> Therefore, any disruption on the levels of this

neurotransmitter in the early deep cerebellar nuclei development may affect the neural network that connects the cerebellum with some limbic structures, being compromising cognitive and behavioral maturation in autism. Moreover, the blood level of serotonin is elevated in autistic subjects<sup>39</sup> and some researchers think that this molecule could be a biomarker of autism for future diagnosis (Figure 3).

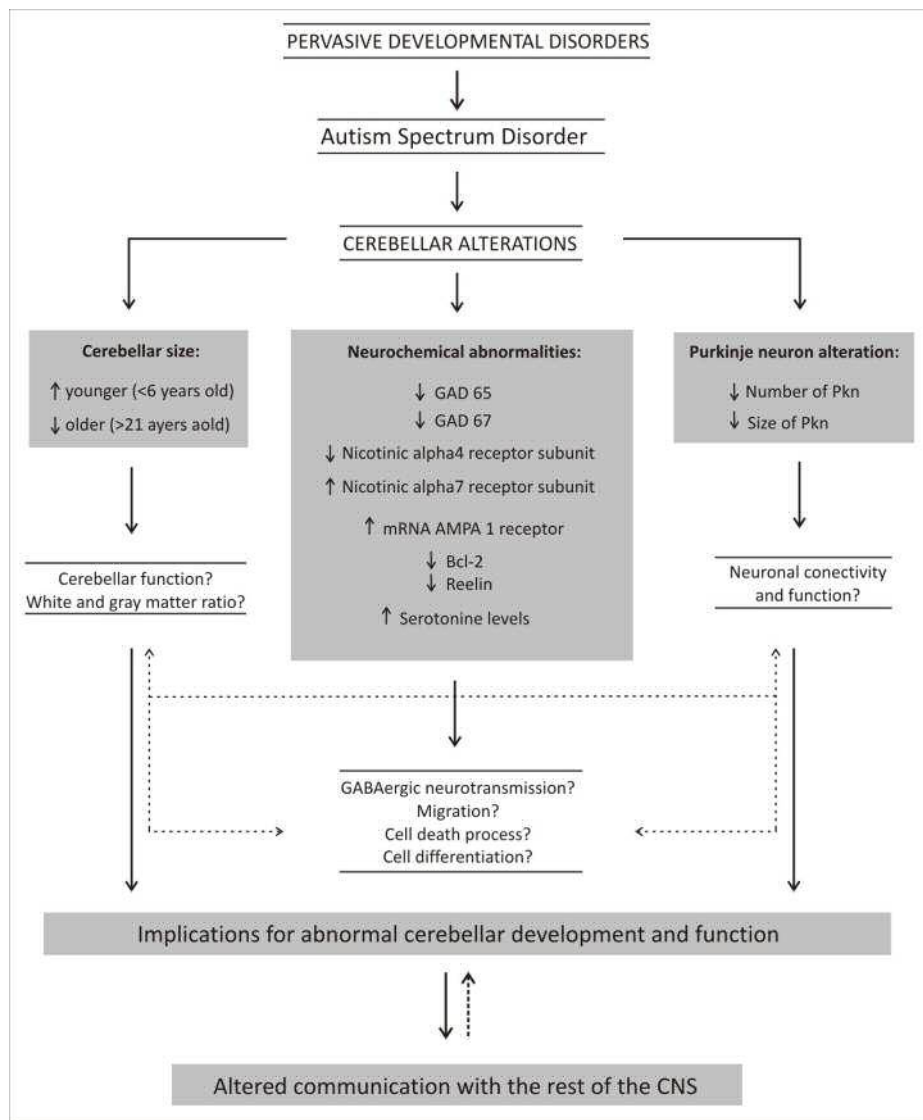


Figure 3. This integrative framework depicts the main cerebellar alterations found in autistic subjects and tries to link them to the immediate neurobiological processes related with the cerebellar function and brain networks that may underlie part of the autistic phenotype.

Despite these particular alterations the lack of a biological biomarker is still there due to the complexity of this disorder that involves many factors. Up to now, we have shown the most relevant abnormalities in the autistic cerebellum going from the anatomical to neurochemical findings in order to look for the events or cues that tell us how the cerebellum is participating in autism, shedding light for a better understanding of this developmental pathology. Although the lack of information to understand autism, there is enough evidence supporting that the altered cerebellum has a significant contribution to autism.

#### **4. VPA in rats: an animal model for the study of autistic-like cerebellar alteration**

Obtaining brain samples from human beings with autism has been an important constraint for the advance of understanding this syndrome. Therefore, the development of animal models to contribute to the study of autism is quite necessary. Ingram et al (2000) published a paper showing a specific cerebellar alteration as seen in autism. They used VPA, an antiepileptic drug with a potent teratogenic activity during pregnancy,<sup>40-42</sup> that mimics in rats the Pkn loss and volume abnormalities of the vermis and hemispheres as those seen in autism.<sup>43</sup> Similar neuroanatomical abnormalities have been reported in mice under VPA treatment.<sup>44</sup> VPA has been associated with autism since epileptic mothers were treated during pregnancy with sodium valproate (salt form of VPA) and gave birth to children with autism-like features.<sup>45-47</sup> Other drugs such as misoprostol and thalidomide have been associated with the same effect. The experimental protocol followed by Ingram et al (2000) associates an abnormal development of the CNS to autism due to the insult given to embryonic rats during the closure of the neural tube (embryonic day 11.5-12). In humans, this occurs on day 28 after fecundation. In addition, the VPA-treated rats have shown disruption in social interactions, altered levels of serotonin,

different sensitivity to pain stimuli and repetitive and stereotype behavior.<sup>43,48-50</sup> such as those reported in autism. Taking data altogether, the use of VPA offers an opportunity for the study of the molecular and cellular mechanisms underlying the cerebellar development and its alterations, as well as their implications on social behavior and sensory integration in autism. Thus, the VPA model has the potential for being a useful tool on autism research.

#### **5. Conclusions**

Here we summarized the most relevant alterations found in the autistic cerebellum. The complexity of this disorder and the limited number of brain samples has made difficult its study, remaining many questions unknown. Therefore, we emphasized the importance to develop animal models in order to understand the neuropathology of autism. Even though the VPA animal model needs to complete its validation, it could be a useful tool for the etiology of autism.

#### **6. Acknowledgements**

This work was supported by CONACyT scholarship 205779 (MPP) and Grant 106531 (MEH). We want to thank Dr. Mike Bowers (University of Maryland) by the linguistic revision.

#### **7. References**

1. Fombone E. The epidemiology of pervasive developmental disorders. In: Bauman and Kemper (Ed.). The neurobiology of autism. 2005 pp 3-22.
2. American Psychological Association. Pervasive developmental disorders. In: Diagnostic and statistical manual of mental disorders 4th ed. Washington DC. 1994 pp 69-81.
3. Bauman M and Kemper T. Limbic and cerebellar abnormalities are also present in an autistic child of normal intelligence. *Neurology* 1990 40: 359.



4. Kemper T and Bauman M. Neuropathology of infantile autism. *J Neuropathol Exp Neurol* 1998 57: 645-652.
5. Sparks B, Friedman S, Shaw D, Aylward E, Echelard D, Artru A, Maravilla K, Munson J, Dawson G, Dager S. Brain structural abnormalities in young children with autism spectrum disorder. *Neurology* 2002 59: 184-192.
6. Amaral D, Schumann C, Nordahl C. The neuroanatomy of autism. *Trends Neurosci* 2008 31: 137-145.
7. Holstege G, Georgiadis J, Paans A, Meiners L, Van der Graaf F, Reinders A. Brain activation during human male ejaculation. *J Neurosci* 2003 23: 9185-9193.
8. Manzo J, Miquel M, Toledo R, Mayor-Mar J, García I, Aranda-Abreu E, Caba M, Hernández M. Fos expression at the cerebellum following non-contact arousal and mating behavior in male rats. *Physiol Behav* 2008 28: 357-363.
9. Miquel M, Toledo R, Garcia LI, Coria-Avila GA, Manzo J. Why should we keep the cerebellum in mind when thinking about addiction? *Curr Drug Abuse Rev* 2009 2: 26-40.
10. Garcia-Martinez R, Miquel M, Garcia LI, Coria-Avila GA, Perez CA, Aranda-Abreu GE, Toledo R, Hernandez ME, Manzo J. Multiunit recording of the cerebellar cortex, inferior olive, and fastigial nucleus during copulation in naive and sexually experienced male rats. *Cerebellum* 2009 9: 96-102.
11. Paredes-Ramos P, Pfaus JG, Miquel M, Manzo J, Coria-Ávila GA. Sexual reward induces Fos in the cerebellum of female rats. *Physiol Behav* 2011 102: 143-148.
12. Hamson D, Csupity A, Gaspar J, Watson N. Analysis of Foxp2 expression in the cerebellum reveals a possible sex difference. *NeuroReport* 2009 20: 611-616.
13. Delgado-García JM. Estructura y función del cerebelo. *Neurología* 2001 33: 635-642.
14. Voogd J. The human cerebellum. *J Chem Neuroanat* 2003 26: 243-252.
15. Brodal P. The central nervous system: structure and function. Oxford University Press, New York. 2010 pp 343-361.
16. Apps R and Garwicz M. Anatomical and physiological foundations of cerebellar information processing. *Neuroscience* 2005 6: 287-311.
17. Manto M. Cerebellar disorders: a practical approach to diagnosis and management. Cambridge University Press, New York. 2010 pp 2-22.
18. Paxinos G and Watson C. The rat brain in stereotaxic coordinates. Academic Press, Sydney. 1998.
19. Courchesne E, Karns CM, Davis HR, Ziccardi R, Carper RA, Tigue ZD, Chisum HJ, Moses P, Pierce K, Lord C, Lincoln AJ, Pizzo S, Schreibman L, Haas RH, Akshoomoff NA, Courchesne RY. Unusual brain growth patterns in early life in patients with autistic disorder: an MRI study. *Neurology* 2001 57: 245-254.
20. Bauman M and Kemper T. Structural brain anatomy in autism: what is evidence? In: Bauman and Kemper (Ed.). *The neurobiology of autism*. 2005 pp 119-145.
21. Webb S, Sparks B, Friedman S, Shaw D, Giedd J, Dawson G, Dager S.

- Cerebellar vermal volumes and behavioral correlates in children with autism spectrum disorder. *Psychiatry Res* 2009 172: 61-67.
22. Bauman M, Kemper T, Arin DM. Pervasive neuroanatomic abnormalities of the brain in three cases of Rett's syndrome. *Neurology* 1995 45: 1581-1586.
  23. Cheung C, Yu K, Fung G, Leung M, Wong C, Li Q, Sham P, Chua S, McAlonan G. Autistic disorders and schizophrenia: related or remote? An anatomical likelihood estimation. *PLoS One* 2010 5: e12233.
  24. McCarthy M, Auger A, Bale T, De Vries G, Dunn G, Forger N, Murray E, Nugent B, Schwarz J, Wilson M. The epigenetics of sex differences in the brain. *J Neurosci* 2009 29: 12815-12823.
  25. Murakami J, Courchesne E, Press G, Yeung-Courchesne R, Hesselink J. Reduced cerebellar hemisphere size and its relationship to vermal hypoplasia in autism. *Arch Neurol* 1989 46: 689-694.
  26. Courchesne E, Muller R, Saitoh O. Brain weight in autism: normal in the majority of cases, megalencephalic in rare cases. *Neurology* 1999 52: 1057-1059.
  27. Courchesne E, Karns C, Davis H, Ziccardi R, Carper R, Tigue Z. Unusual brain growth patterns in early life in patients with autistic disorder: an MRI study. *Neurology* 2001 57: 245-254.
  28. Palmen S, Van Engeland H, Hof P, Schmitz C. Neuropathological findings in autism. *Brain* 2004 127: 2572-2583.
  29. Whitney E, Kemper T, Rosene D, Bauman M, Blatt G. Density of cerebellar basket and stellate cells in autism: evidence for a late developmental loss of Purkinje cells. *J Neurosci Res* 2009 87: 2245-2254.
  30. Fatemi S, Halt A, Realmuto G, Earle J, Kist D, Thuras P, Merz A. Purkinje cell size is reduced in cerebellum of patients with autism. *Cell Mol Neurobiol* 2002 22: 171-175.
  31. DeLong R. The cerebellum in autism. In: Coleman M (Ed.). *The neurology of autism*. 2005 pp 75-90.
  32. Fatemi S, Stary J, Halt A, Realmuto G. Dysregulation of reelin and Bcl-2 proteins in autistic cerebellum. *J Autism Dev Disord* 2001 31: 529-535.
  33. Fatemi S. The role of reelin in pathology of autism. *Mol Psychiatry* 2002 7: 919-92.
  34. Fatemi S, Halt A, Stary J, Kanodia R, Schulz S, Realmuto G. Glutamic decarboxylase 65 and 67 kDa proteins are reduced in autistic parietal and cerebellar cortices. *Biol Psychiatry* 2002 52: 805-810.
  35. Chugani D. Understanding alterations during human development with molecular imaging: role in determining serotonin and GABA mechanism in autism. In: Blatt G (Ed.). *The neurochemical basis of autism*. 2010 pp 83-93.
  36. Lee M, Martin-Ruiz C, Graham A, Court J, Jaros E, Perry R, Iversen P, Bauman M, Perry E. Nicotinic receptor abnormalities in the cerebellar cortex in autism. *Brain* 2002 125: 1483-1495.
  37. Purcell A, Jeon O, Zimmerman A, Blue M, Pevsner J. Postmortem brain abnormalities of the glutamate neurotransmitter system in autism. *Neurology* 2011 57: 1618-1628.

38. Chugani D, Musik O, Rothermal R, Behen M, Chakraborty P, Mangner T, da Silva E, Chugoni H. Altered serotonin synthesis in the dentatothalamocortical pathway in autistic boys. *Ann Neurol* 1997 42: 666-669.
39. Anderson G, Horne W, Chatterjee, Cohen D. Hyperserotonemia of autism. *Ann NY Acad Sci* 1990 600: 331-340.
40. Arndt T, Stodgell C, Rodier P. The teratology of autism. *Int J Dev Neurosci* 2005 23: 189-199.
41. Ornoy A. Neuroteratogens in man: An overview with special emphasis on the teratogenicity of antiepileptic drugs in pregnancy. *Reprod Toxicol* 2006 22: 214-226.
42. Ornoy A. Valproic acid in pregnancy: how much we are endangering the embryo and fetus? *Reprod Toxicol* 2009 28: 1-10.
43. Ingram J, Peckham S, Tisdale B, Rodier M. Prenatal exposure of rats to valproic acid reproduces the cerebellar anomalies associated with autism. *Neurotoxicol Teratol* 2000 22: 319-324.
44. Wagner G, Reuhl K, Cheh M, McRae P, Halladay A. A new neurobehavioral model of autism in mice: pre and postnatal exposure to sodium valproate. *J Autism Dev Disord* 2006 36: 779-793.
45. Christianson A, Chesler N, Kromberg J. Fetal valproate syndrome: clinical and neurodevelopmental features in two sibling pairs. *Dev Med Child Neurol* 1994 36: 357-369.
46. William P and Hersh J. A male with fetal valproate syndrome and autism. *Dev Med Child Neurol* 1997 39: 632-634.
47. Williams P, King J, Cunningham M. Fetal valproate syndrome and autism: additional evidence of an association. *Dev Med Child Neurol* 2001 43: 202-206.
48. Dufour-Rainfray D, Vourc'h P, Le Guisquet A, Garreau L, Ternant D, Bodard S, Jaumain E, Gulhan Z, Belzung C, Andres C, Chalon S, Guilloteau D. Behavior and serotonergic disorders in rats exposed prenatally to valproate: A model for autism. *Neurosci Lett* 2010 470: 55-59.
49. Narita N, Kato M, Tazoe M, Miyazaki K, Narita M, Okado N. Increased monoamine concentration in the brain and blood of fetal thalidomide- and valproic acid-exposed rat: putative animal model for autism. *Pediatr Res* 2002 52: 576-579.
50. Schneider T and Przewlocki R. Behavioral alterations in rats prenatally exposed to valproic acid: animal model of autism. *Neuropsychopharmacology* 2005 30: 80-89.