

BLOQUE II: TRONCO

COLUMNA VERTEBRAL

VÉRTEBRAS. ARTICULACIONES
ESTUDIOS DE CONJUNTO

Dra. María-Trinidad Herrero Ezquerro
Anatomía Funcional (9S7)

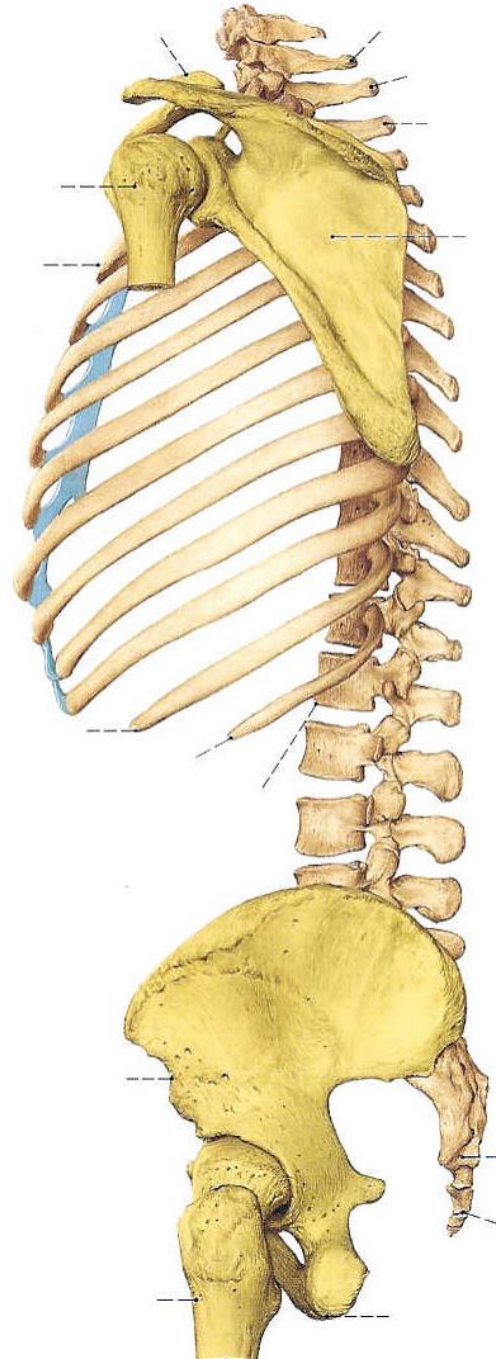
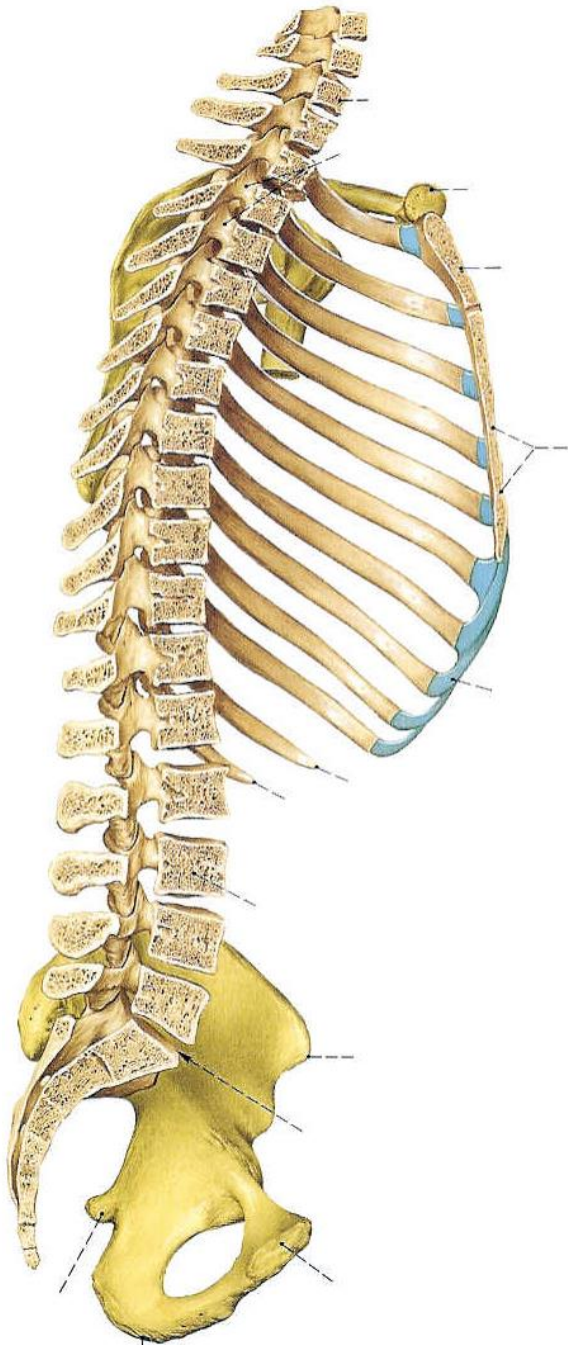
1º Maestro Especialista en Educación Física. Curso Académico 2002-2003

TRONCO

Columna Vertebral

Regiones:

cervical	7
dorsal	12
lumbar	5
sacra	5
coccígea	2-4



VÉRTEBRA TIPO

Hueso irregular corto

AGUJERO VERTEBRAL

CUERPO

ARCO VERTEBRAL

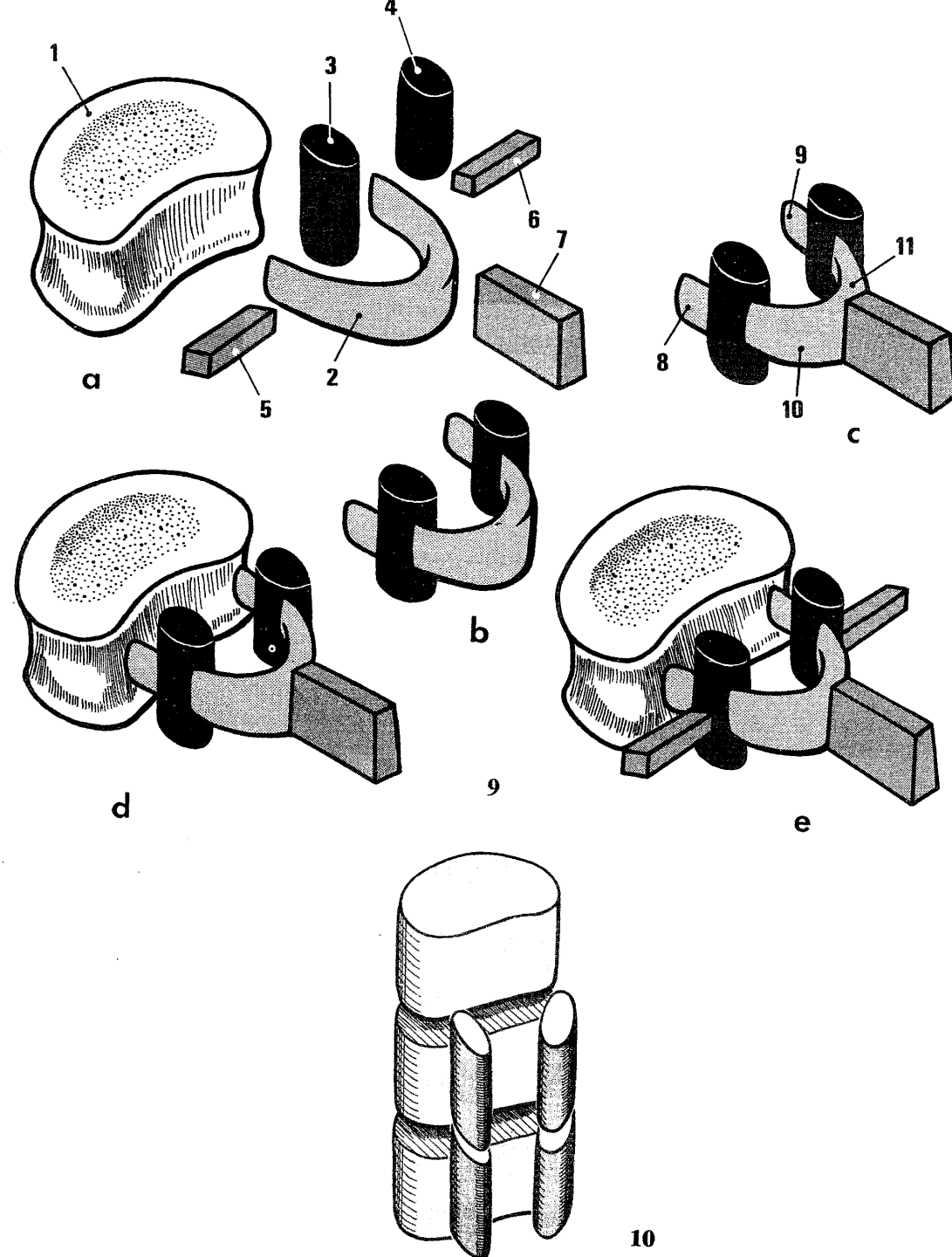
PEDÍCULO

LÁMINA

APÓFISIS ESPINOSA

APÓFISIS TRANSVERSA

APÓFISIS ARTICULARES



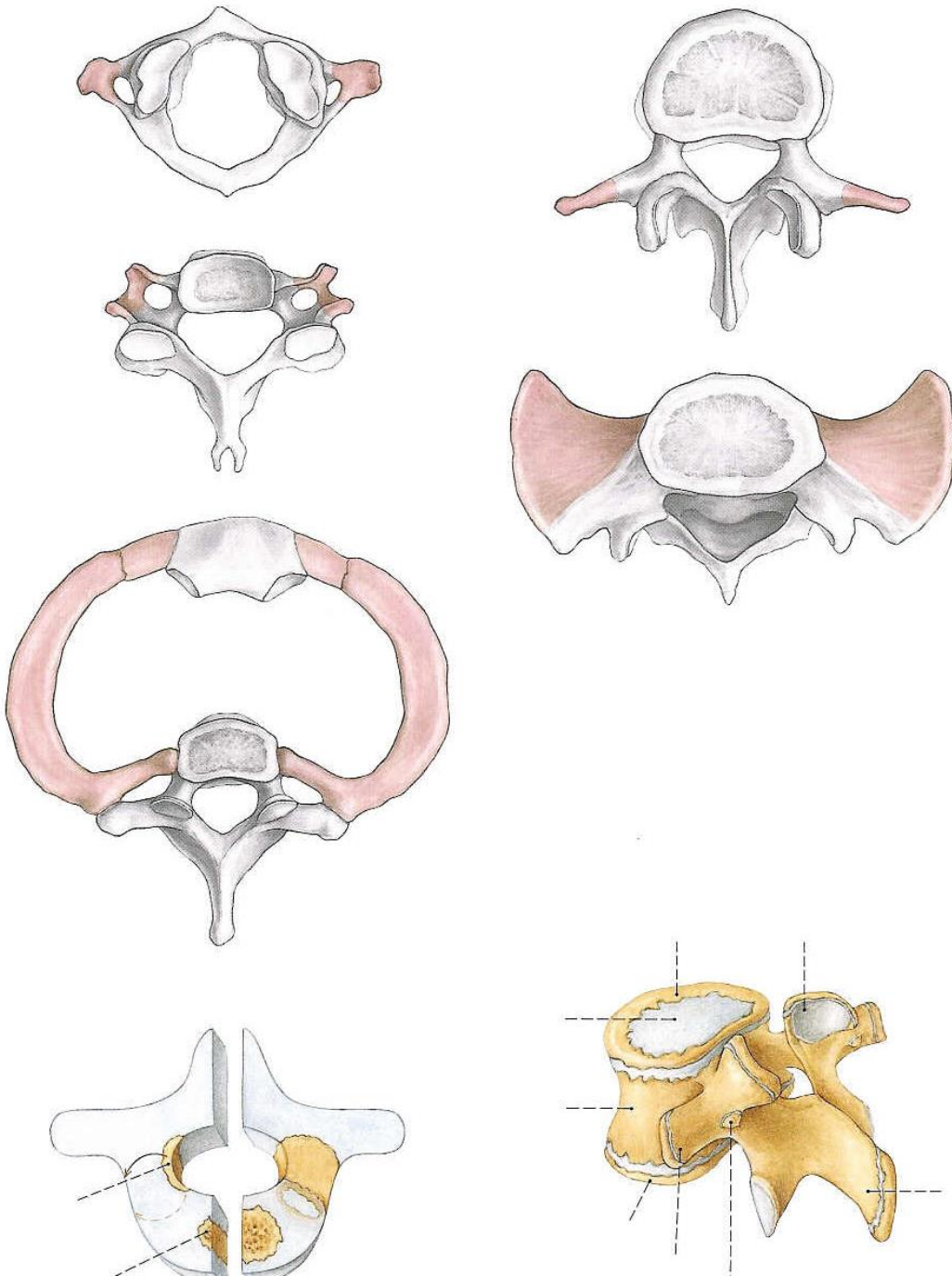
VÉRTEBRAS

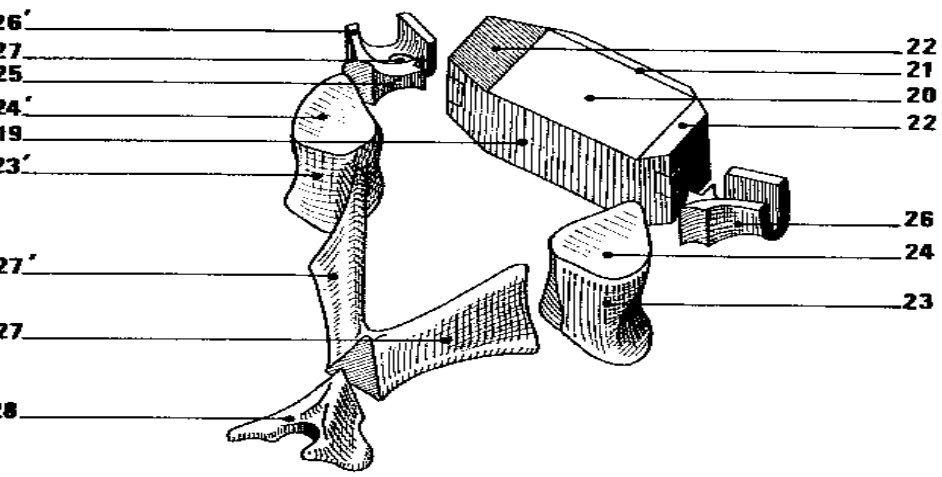
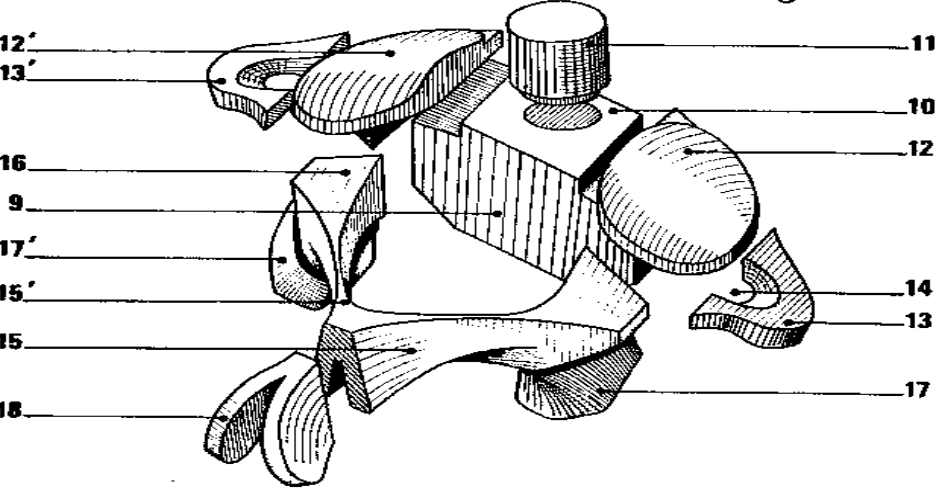
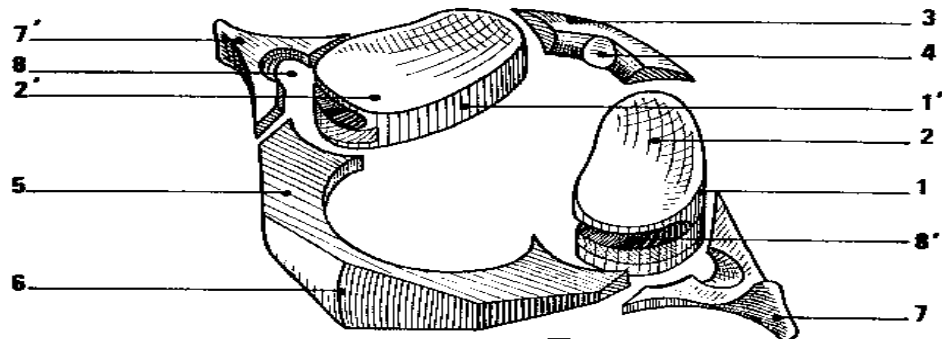
CERVICALES
TORÁCICAS
LUMBARES

ESPECIALES:
ATLAS
AXIS

TORÁCICAS
LUMBARES

SACRO
COCCIX



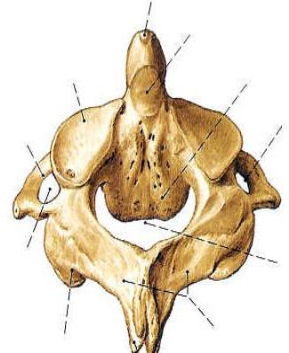
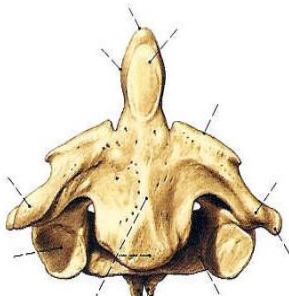
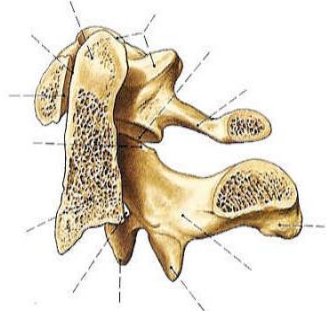
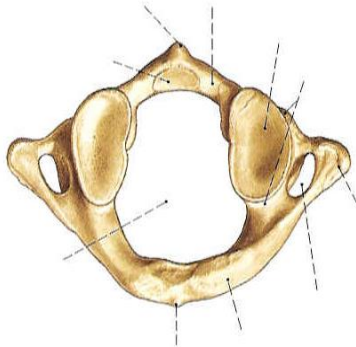
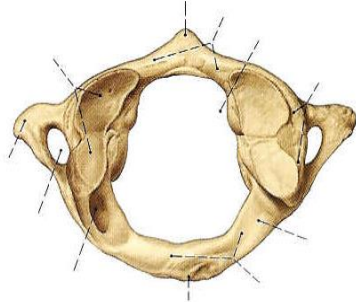
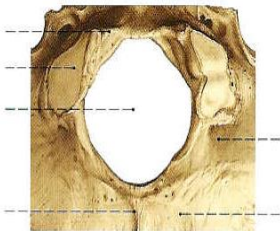


ATLAS

AXIS

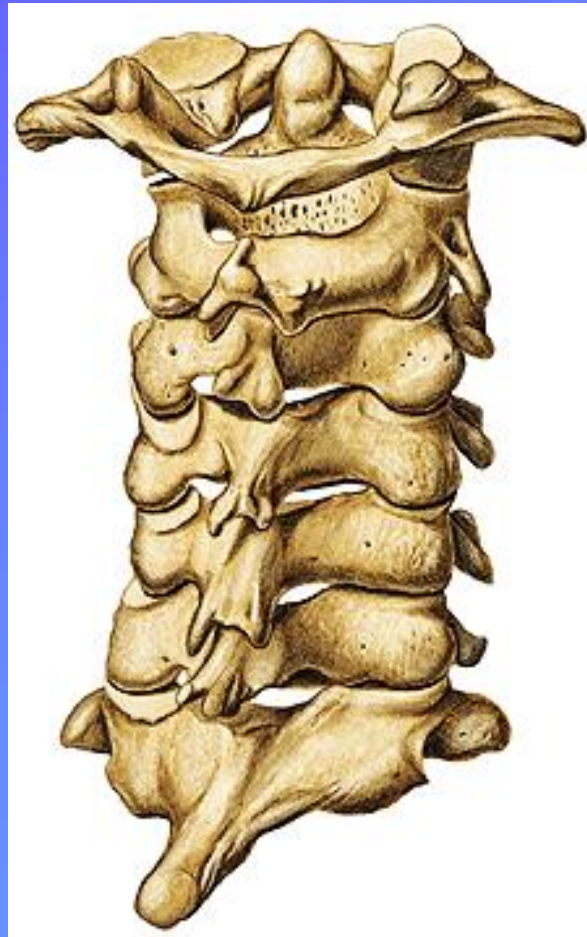CERVICAL TIPO

Cóndilos Occipitales



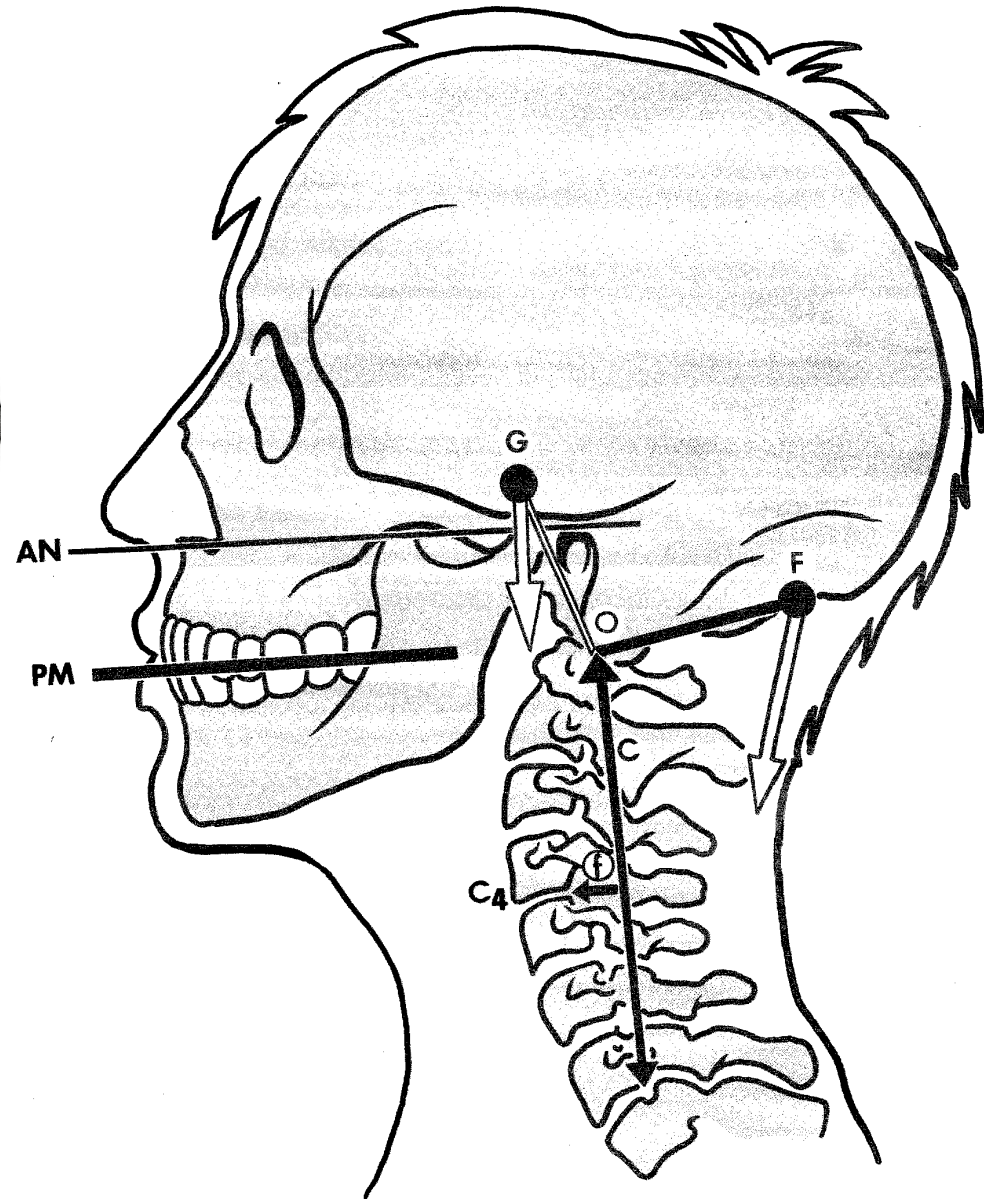
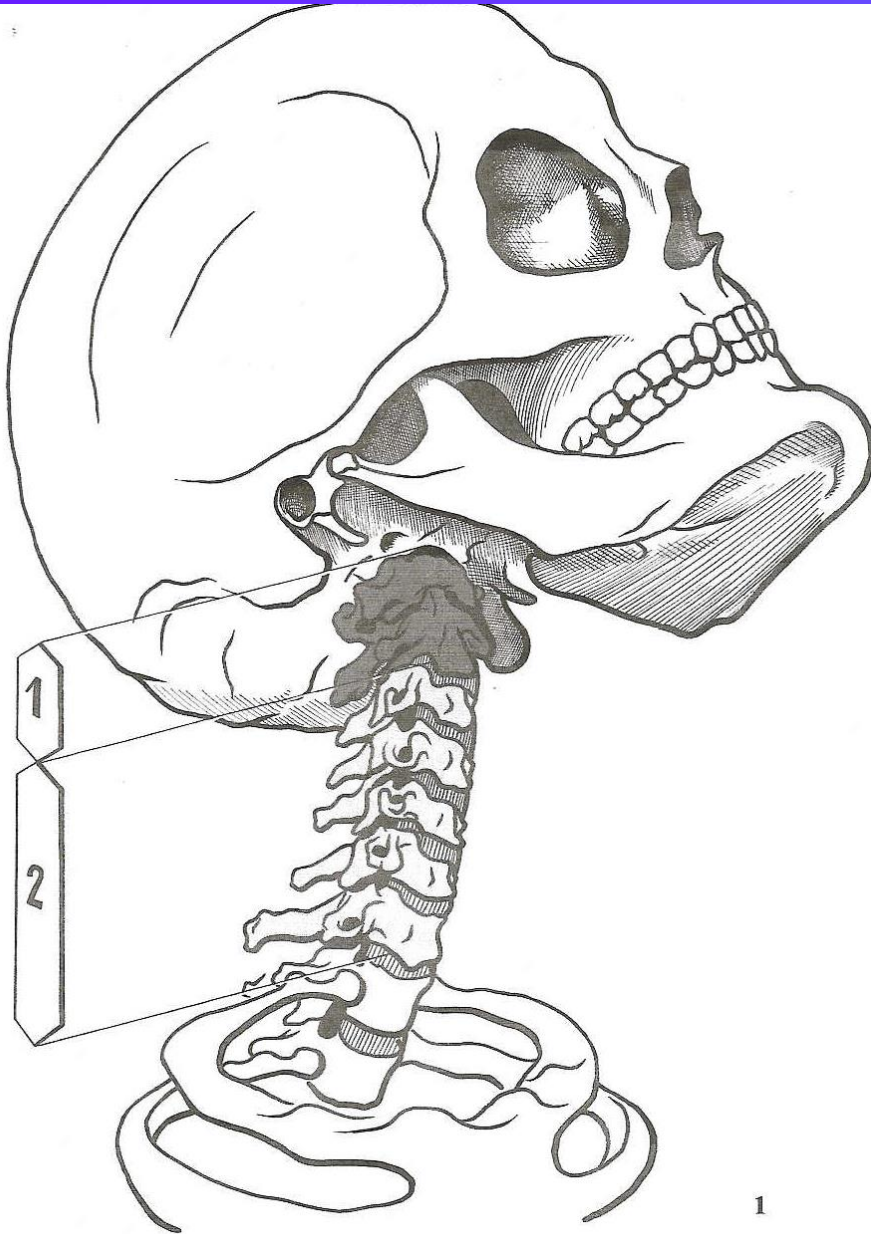
ATLAS

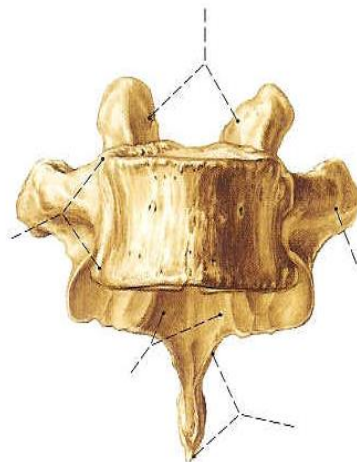
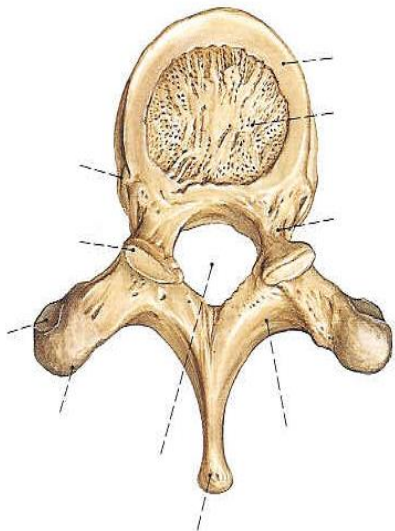
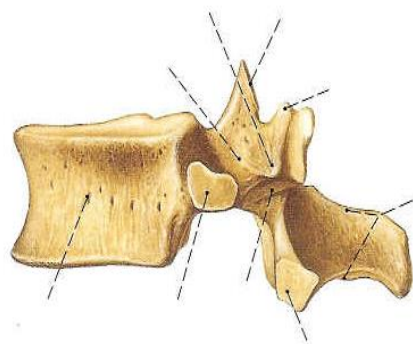
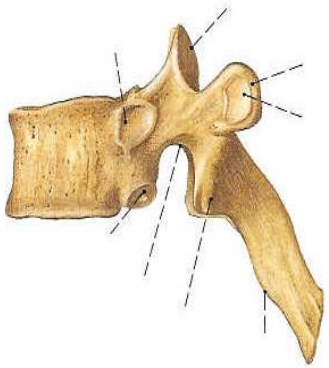
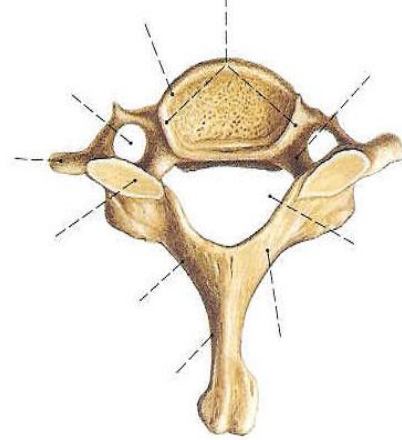
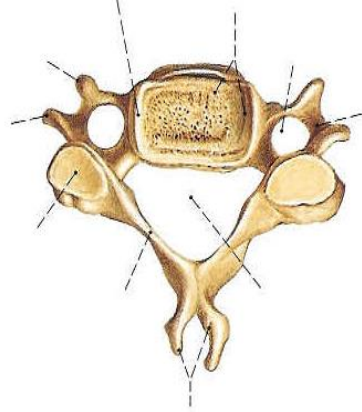
AXIS



SEGMENTO CERVICAL

ATLAS - AXIS : ARTICULACIÓN EN PIVOTE





CERVICALES

TORÁCICAS

LUMBARES

ARTICULACIONES INTERVERTEBRALES

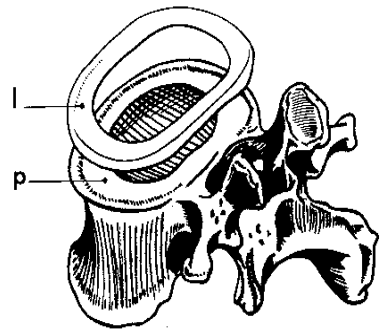
ARTICULACIÓN CARTILAGINOSA

DISCO INTERVERTEBRAL

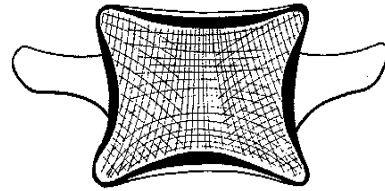
ANILLO FIBROCARILAGINOSO NÚCLEO PULPOSO

DEFORMACIÓN ELÁSTICA

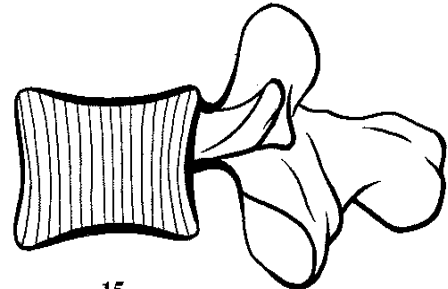
DISTRIBUYE LA TENSIÓN



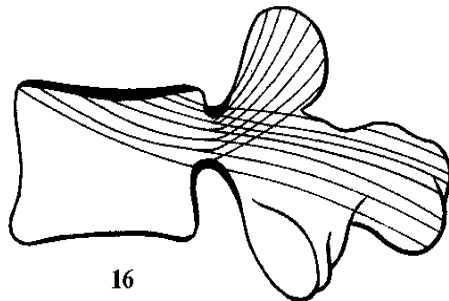
13



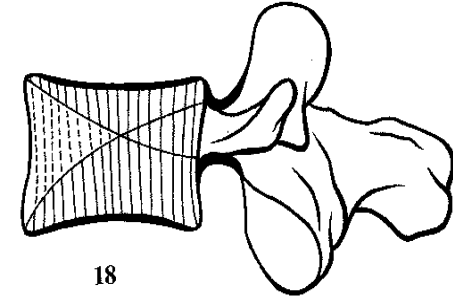
14



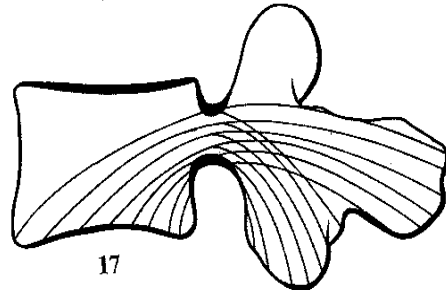
15



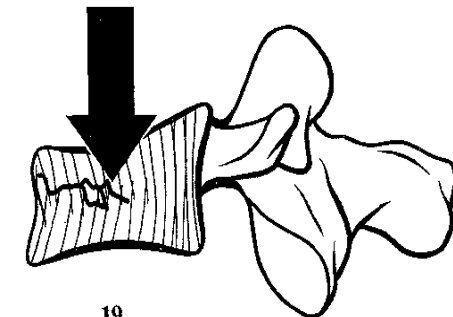
16



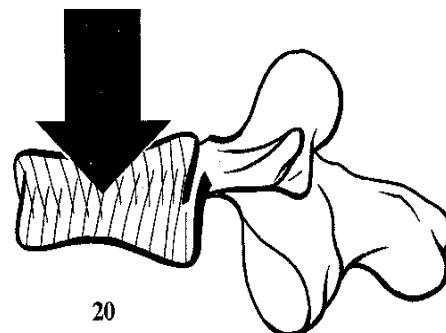
18



17



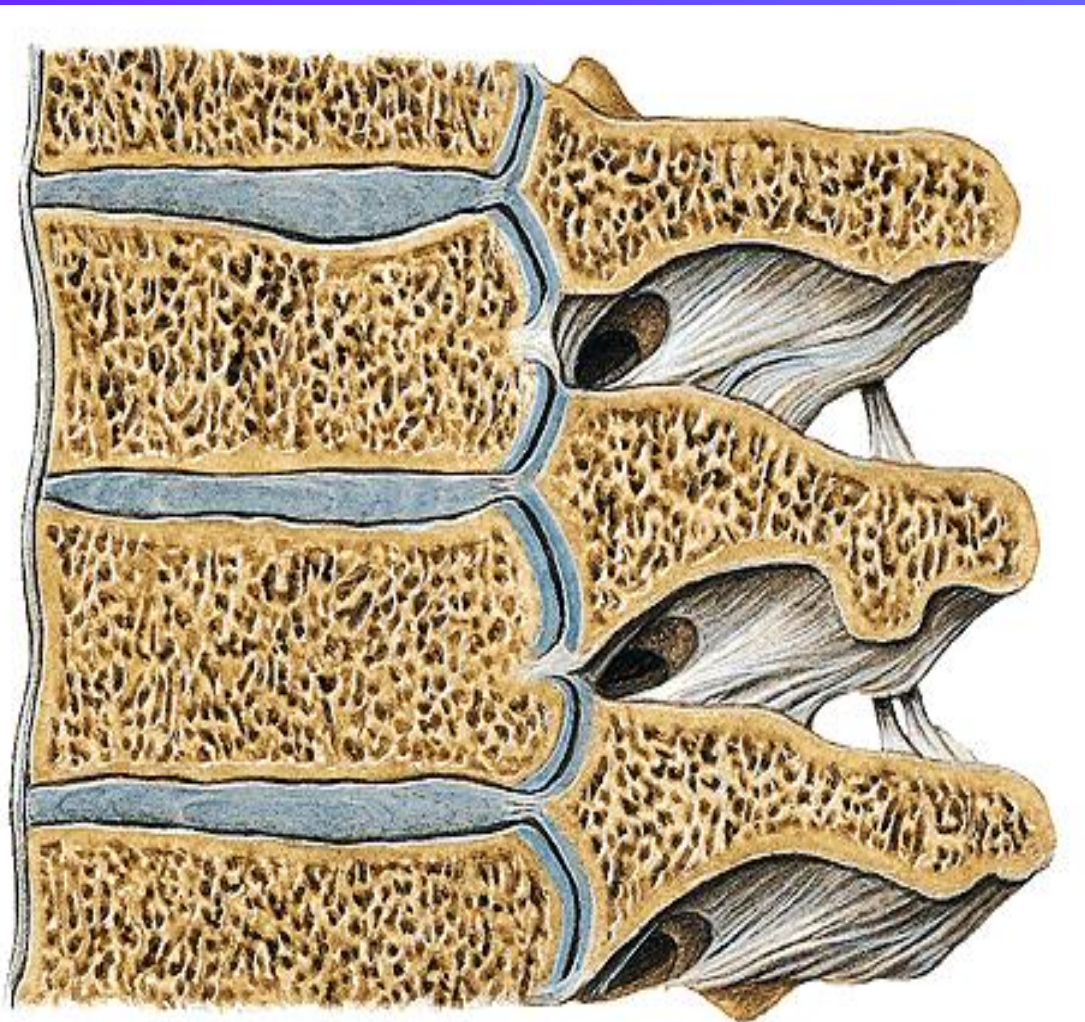
19



20

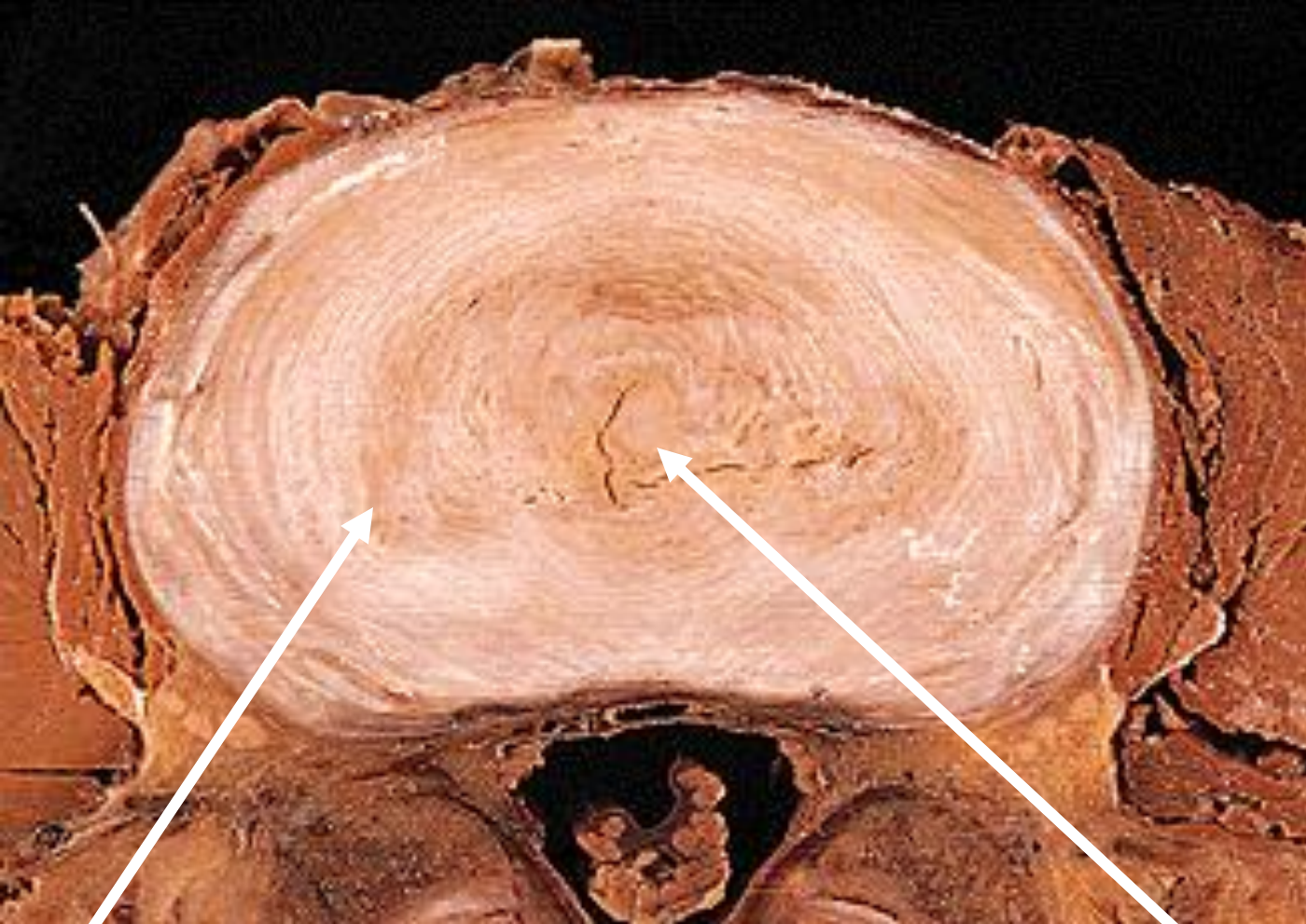Articulación cartilaginosa:
Articulaciones sinoviales:

discos vertebrales
carillas articulares



Cartílago articular

Ligamentos

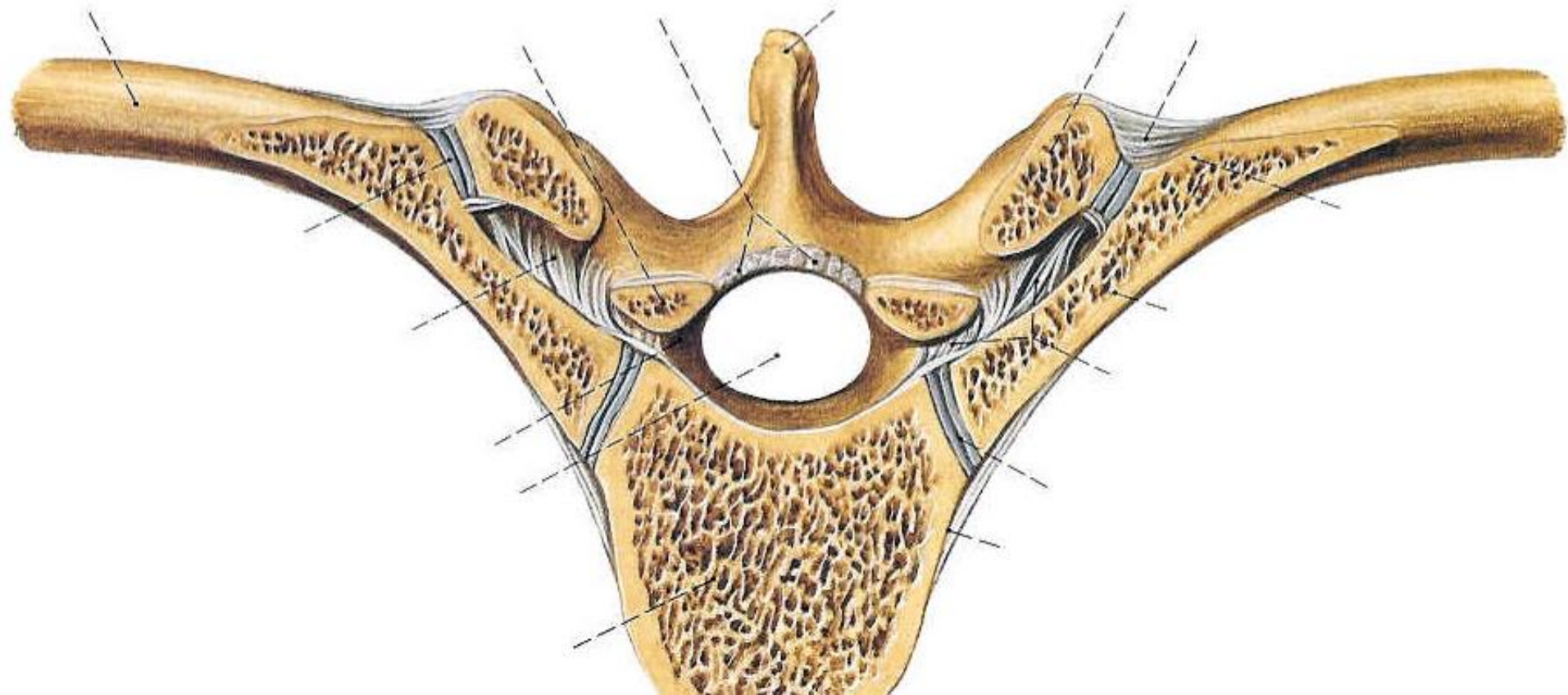


Anillo fibrocartilaginoso

Núcleo Pulposo

Arcos vertebrales: ARTICULACIONES SINOVIALES

DESLIZAMIENTO LIGAMENTOS DE UNIÓN UNIONES COSTALES



CURVADURAS

LORDOSIS

cervical
lumbar

CIFOSIS

dorsal
sacra

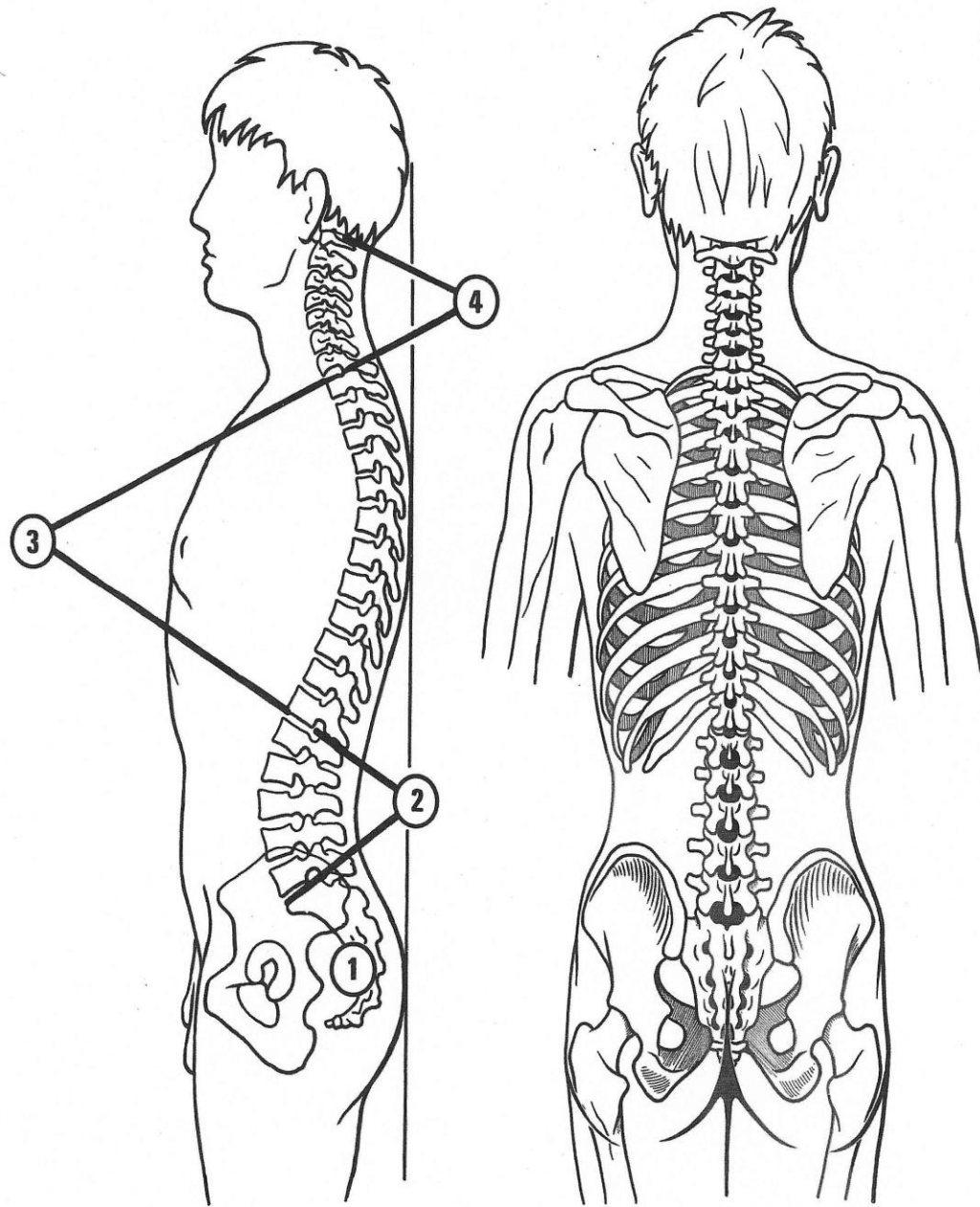
SINUOSIDAD - ESCOLIOSIS

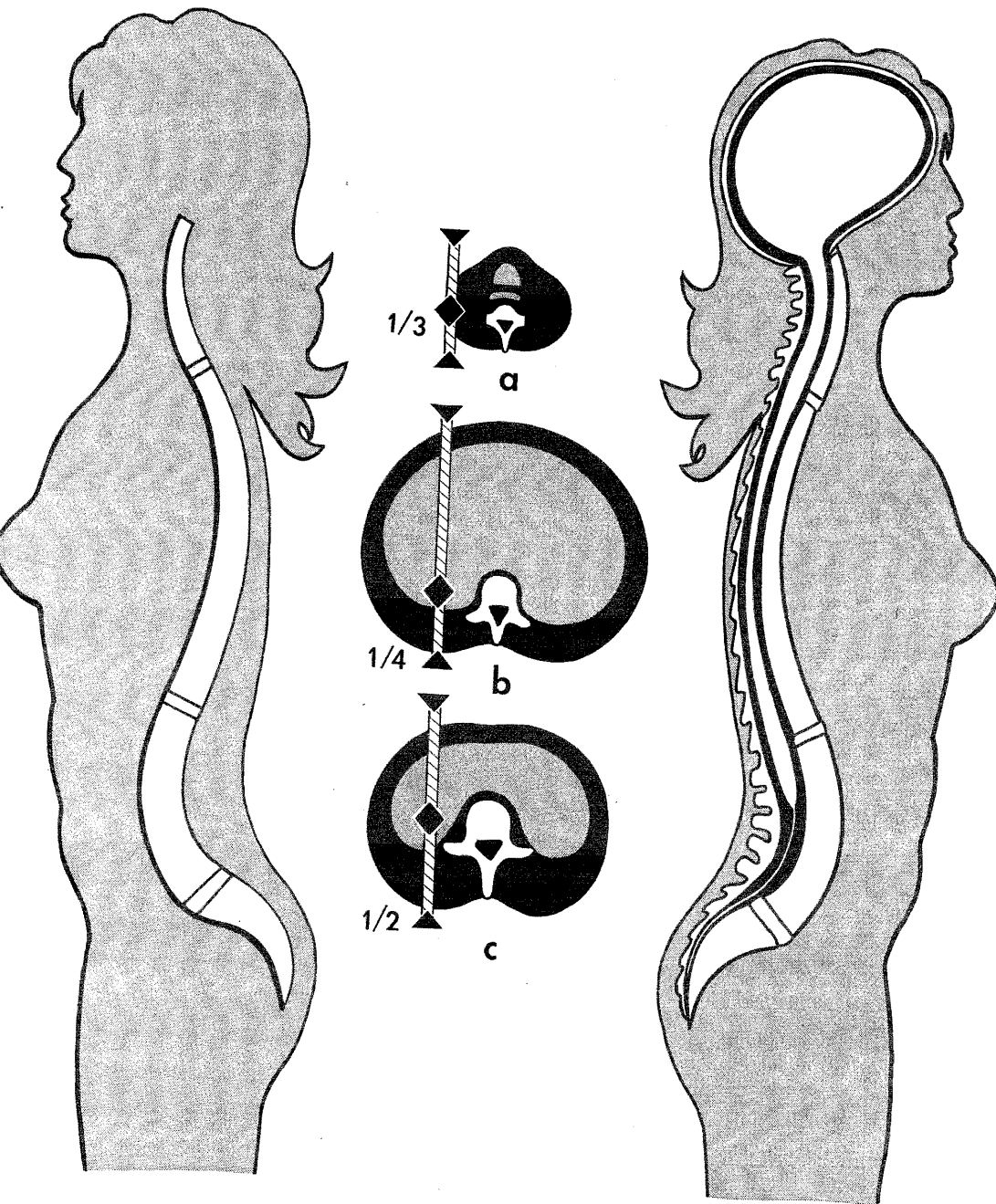
al nacer recta

LC- 2 meses

LL - al andar

CD- compensación





3

4

Varían
en varón y mujer

la mujer embarazada
lordosis exagerada

RAQUIS

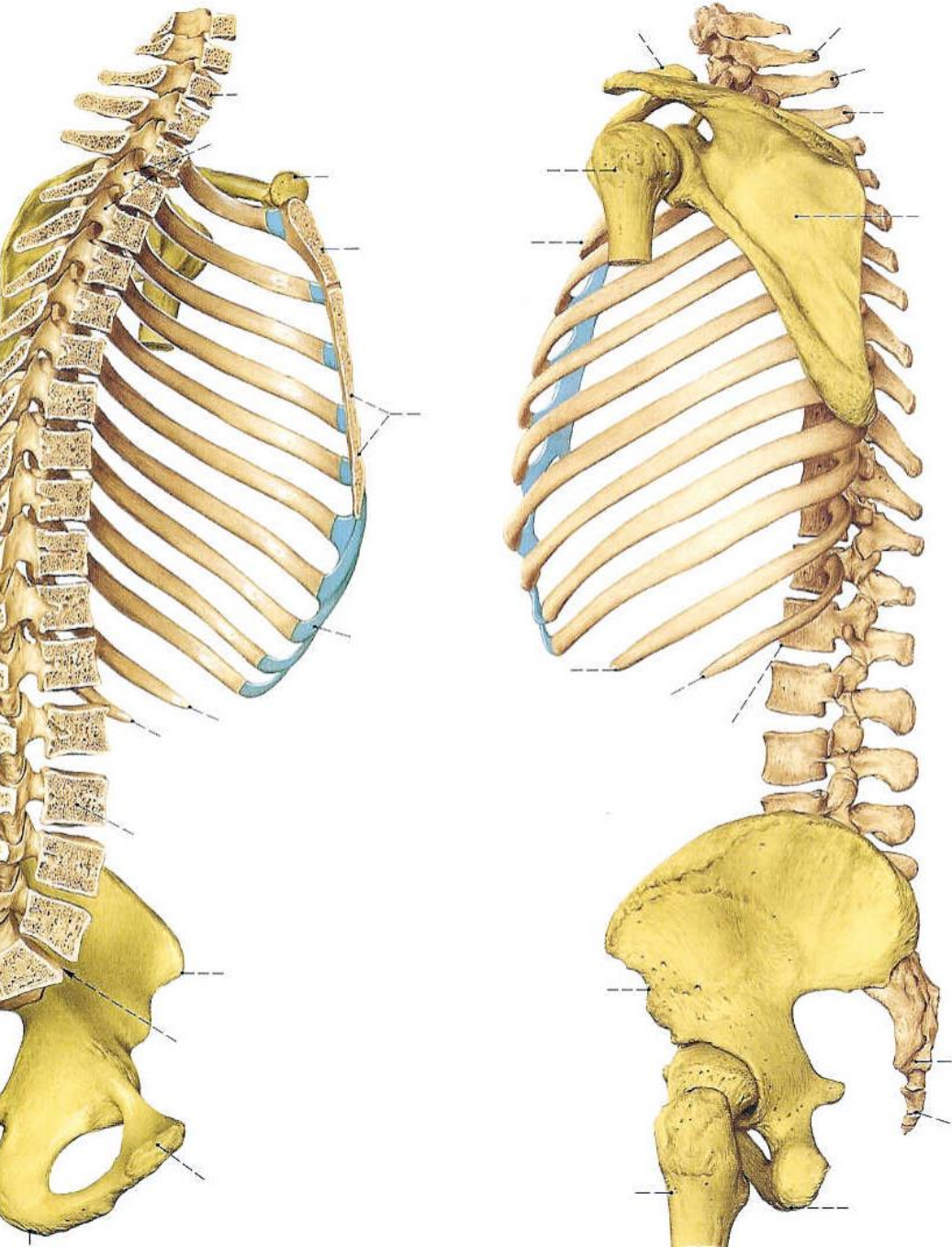
CENTRO DE GRAVEDAD

CERVICAL - a

TORÁCICO - b

LUMBAR -c

PROTEGE AL SNC



Sistema Nervioso Central y Periférico

- 1. Canal Vertebral**
médula espinal
- 2. Agujeros de Conjunción**
nervios raquídeos
vasos espinales

Dolor ciático o irritación:
a.c. cerrado
hernia de disco

PELVIS

HUESO COXAL

ILION

ISQUIÓN

PUBIS

ACETÁBULO

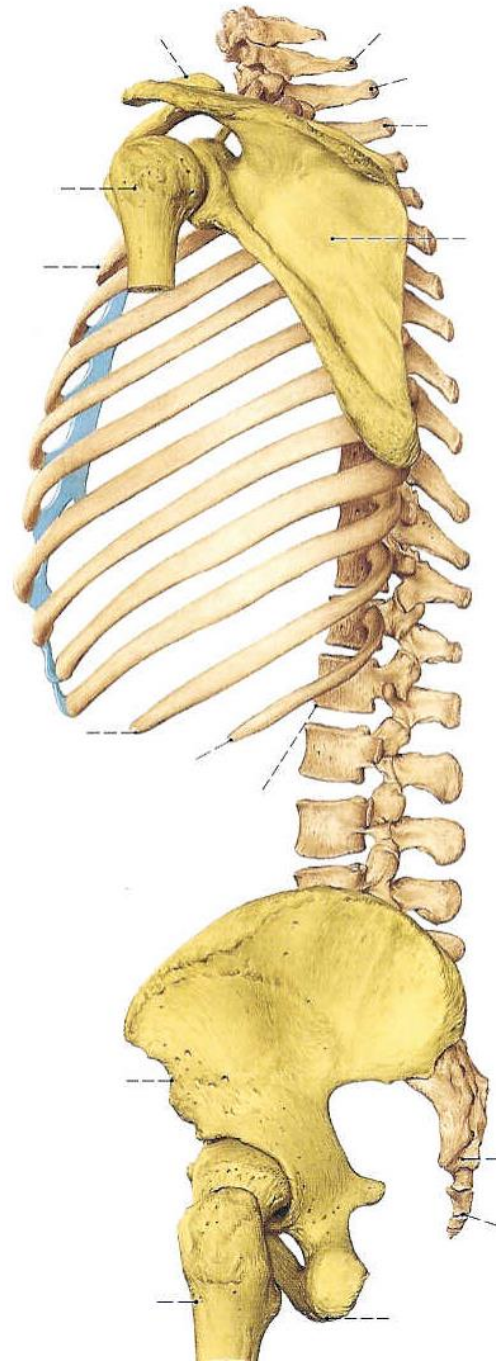
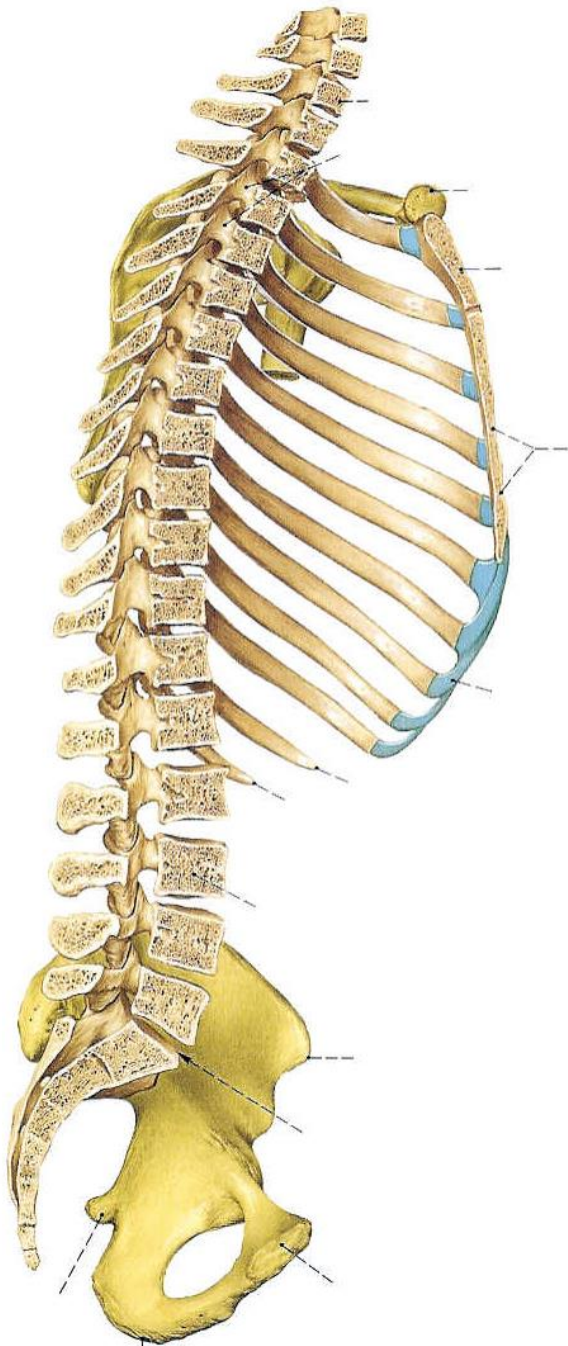
ART. COXO FEMORAL

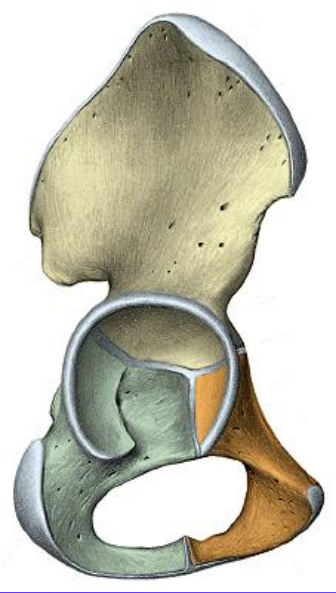
ART. SACROILIACA

SÍNFISIS PÚBICA

PELVIS MAYOR

PELVIS MENOR

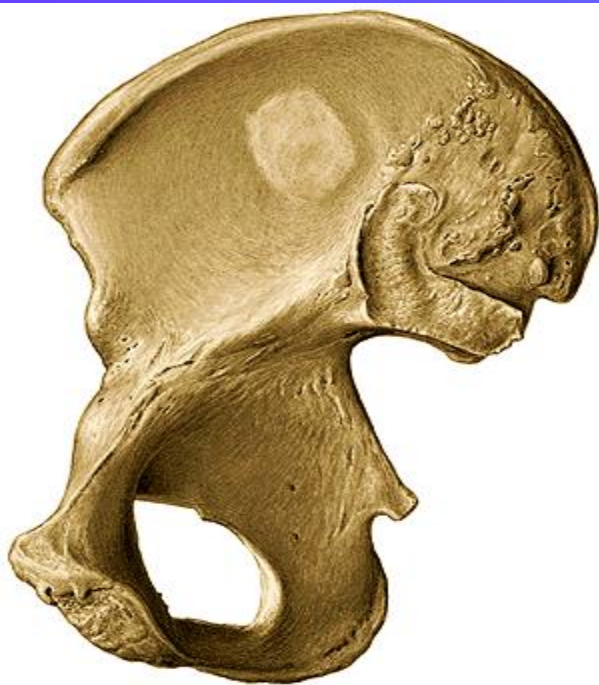



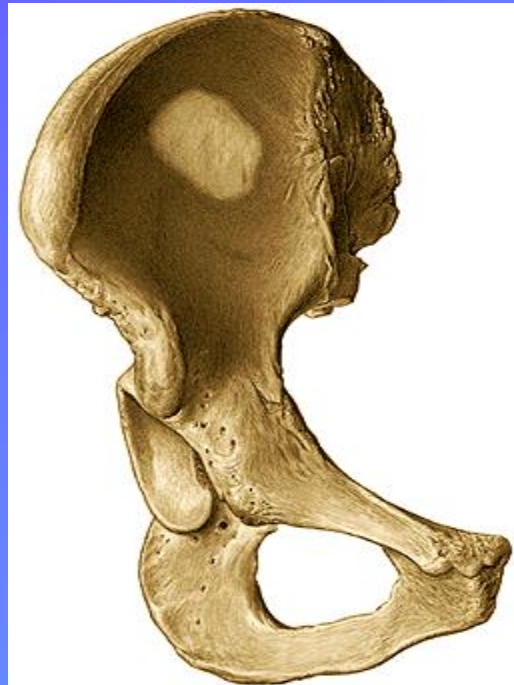COXAL

ILEON - ISQUIION - PUBIS

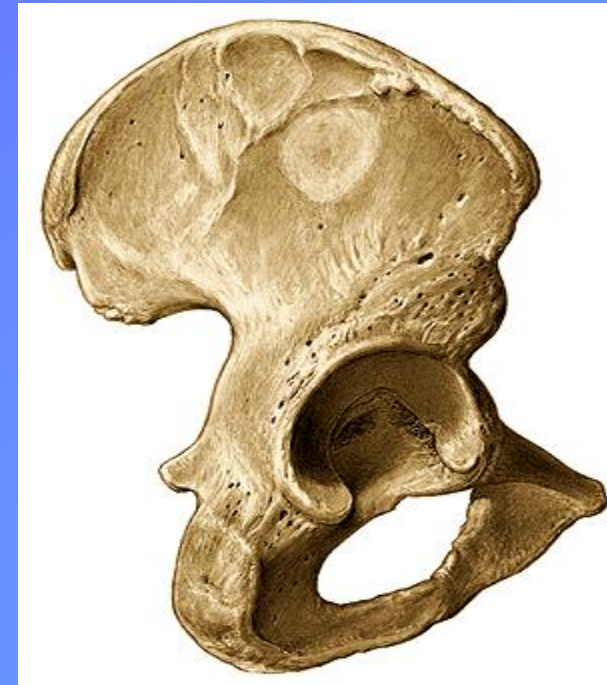
Vista Medial



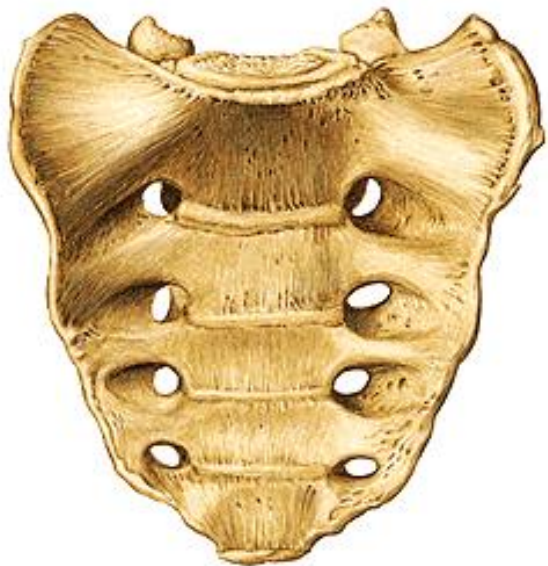
Vista Anterior



Vista Lateral



Vista Anterior

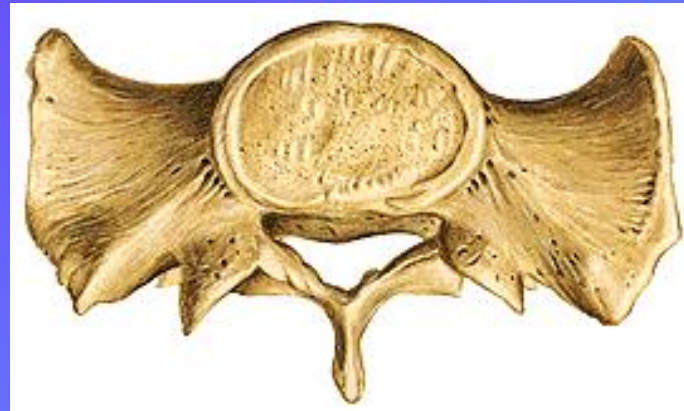
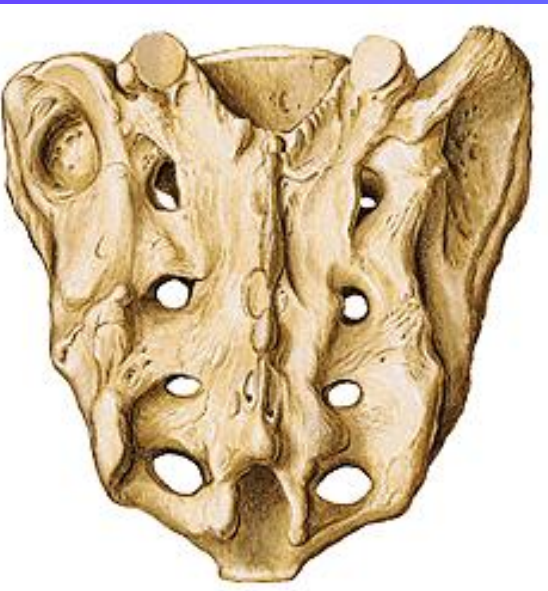

Vista Lateral

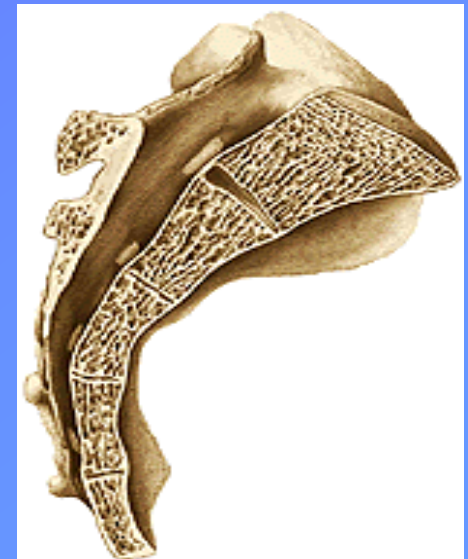

HUESO SACRO

Vista Posterior



Sección Sagital

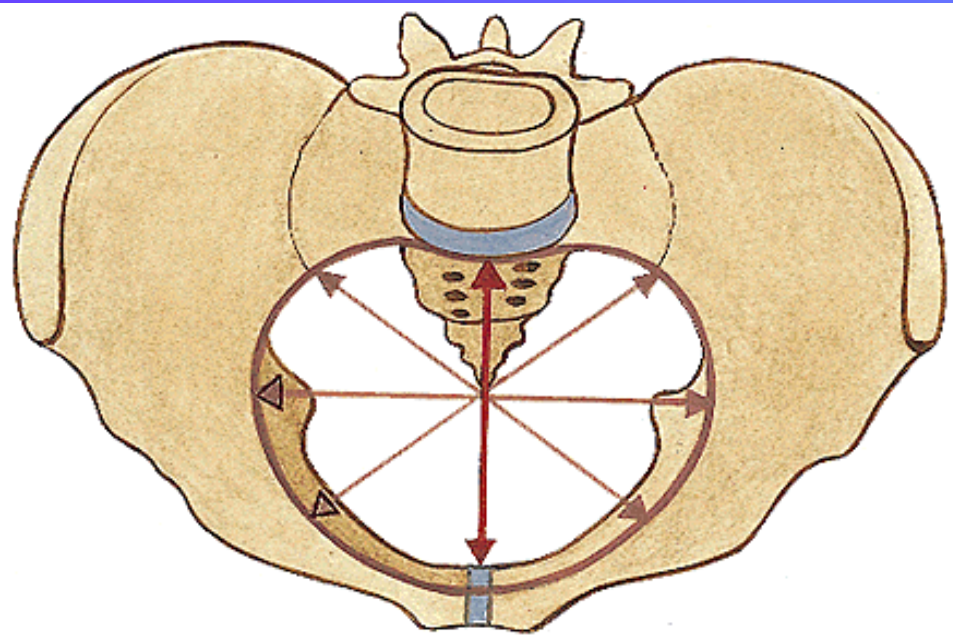
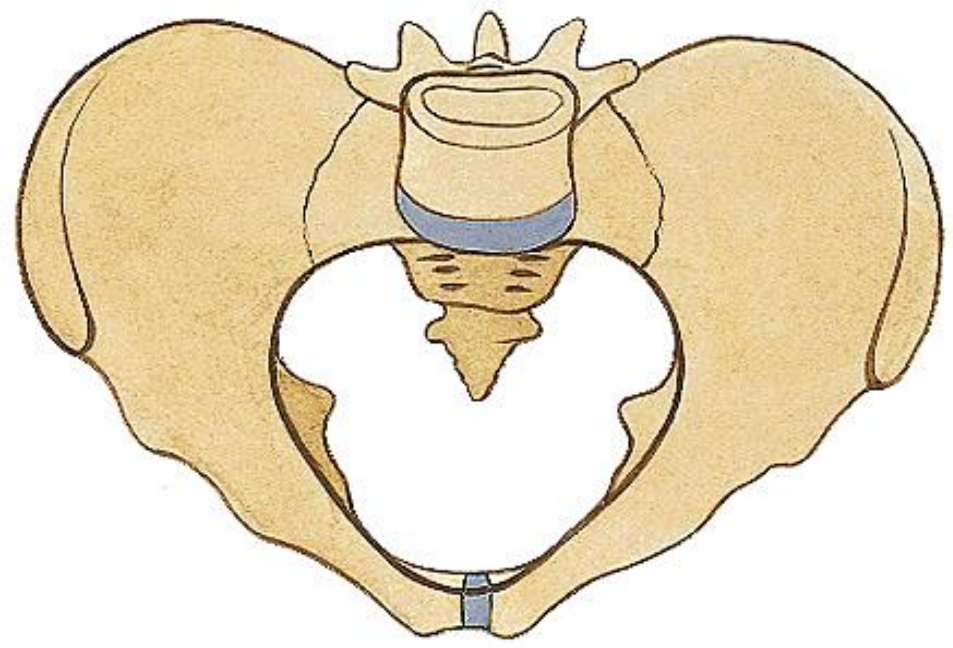


Vista Superior

DIFERENCIAS SEXUALES

PELVIS MASCULINA:
mas estrecha x promontorio (AP)

PELVIS FEMENINA
* las alas del ilion mas separadas
* diametro transverso mayor



Diámetros:

Anteroposterior
Congugado Diagonal
Transverso
Oblicuo
Interespinoso

TÓRAX

Vértebras Torácicas o Dorsales

Esternón

Costillas

Cartílagos Costales

Clavícula - Omóplato

TORAX ÓSEO

VERTEBRAS TORÁCICAS

ESTERNON

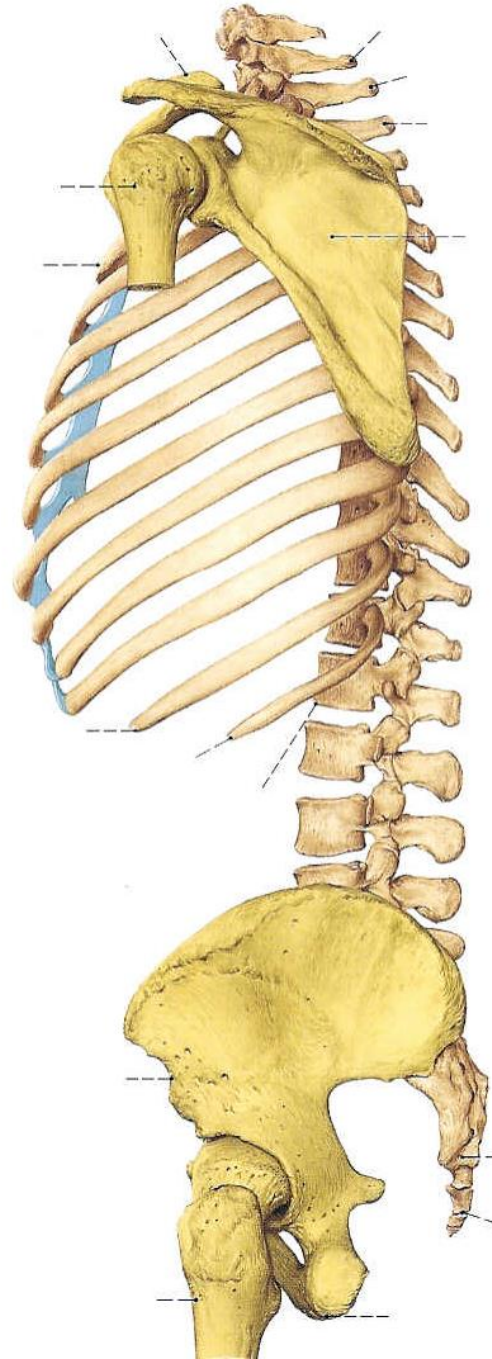
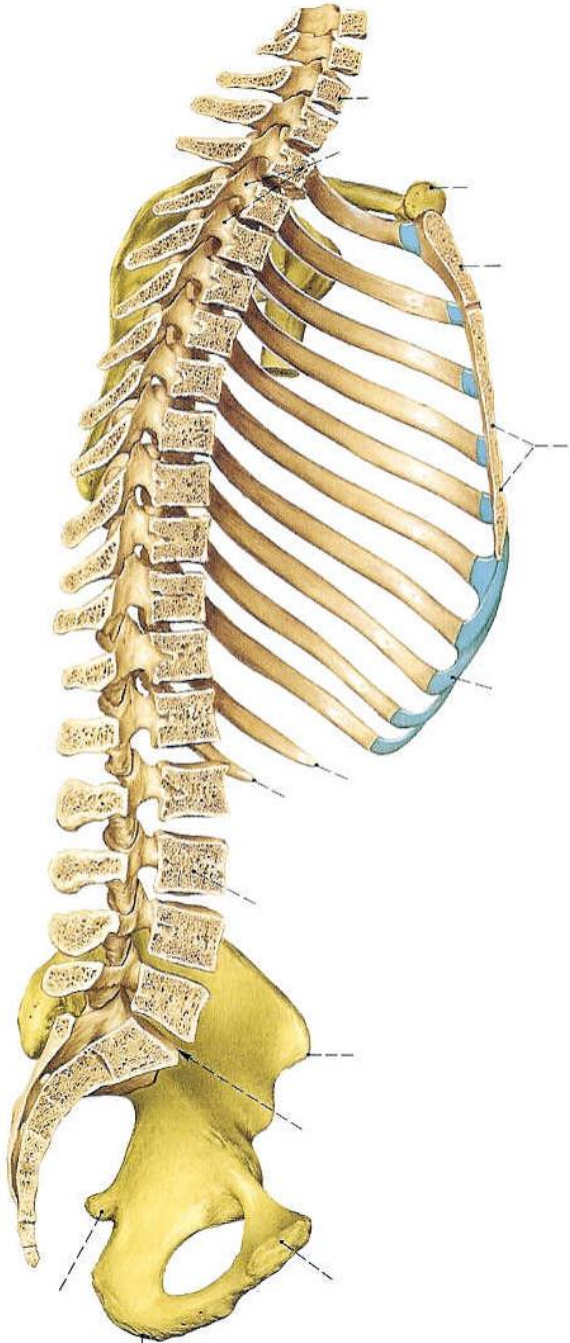
COSTILLAS

CARTÍLAGOS COSTALES

CLAVÍCULA - OMÓPLATO

ORIFICIO CRANEAL

ORIFICIO CAUDAL



TORAX ÓSEO

VERTEBRAS TORÁCICAS

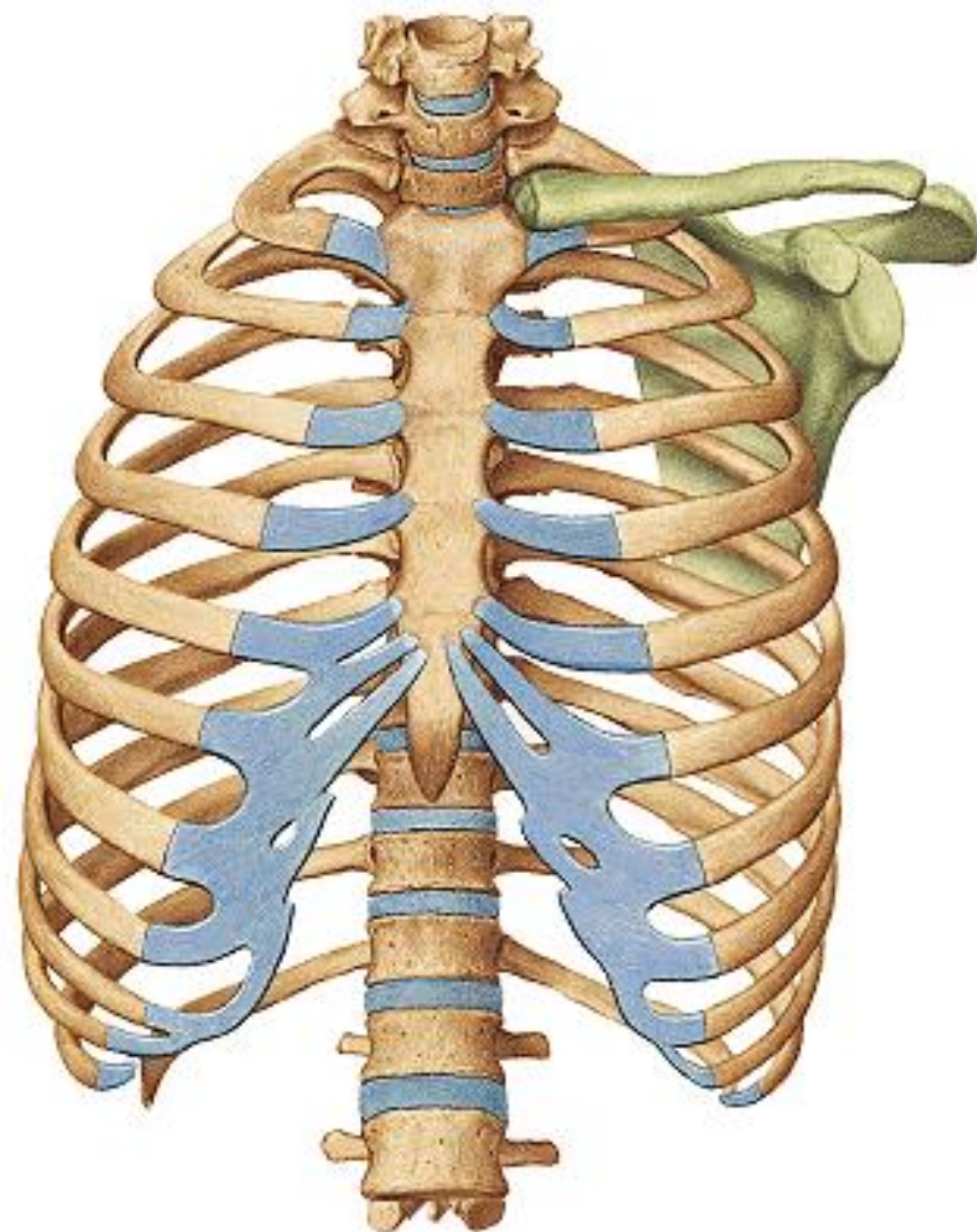
ESTERNON

COSTILLAS

CARTÍLAGOS COSTALES

CLAVÍCULA - OMÓPLATO

ORIFICIO CRANEAL
ORIFICIO CAUDAL



ESTERNON

Hueso esponjoso
SINCONDROSIS

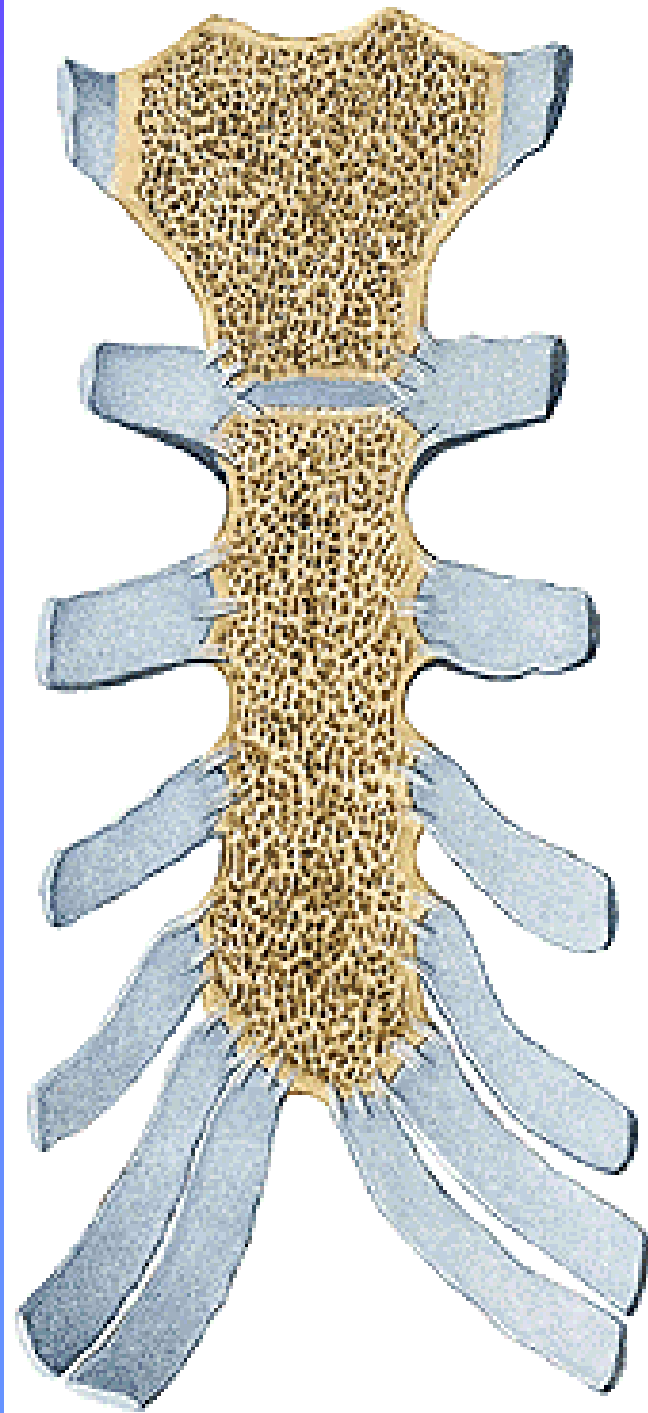
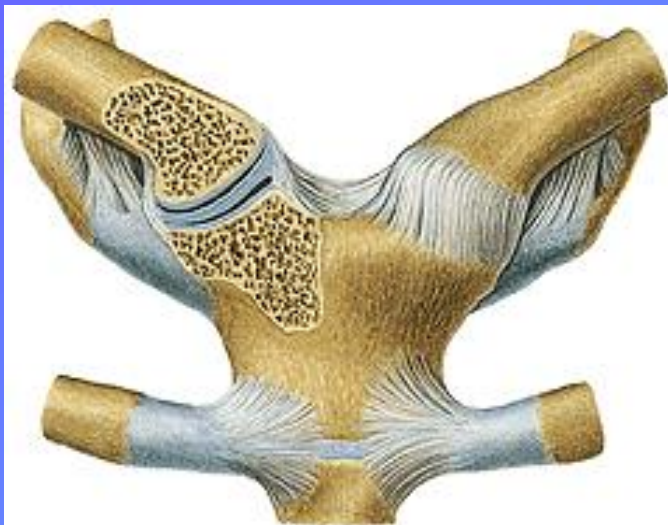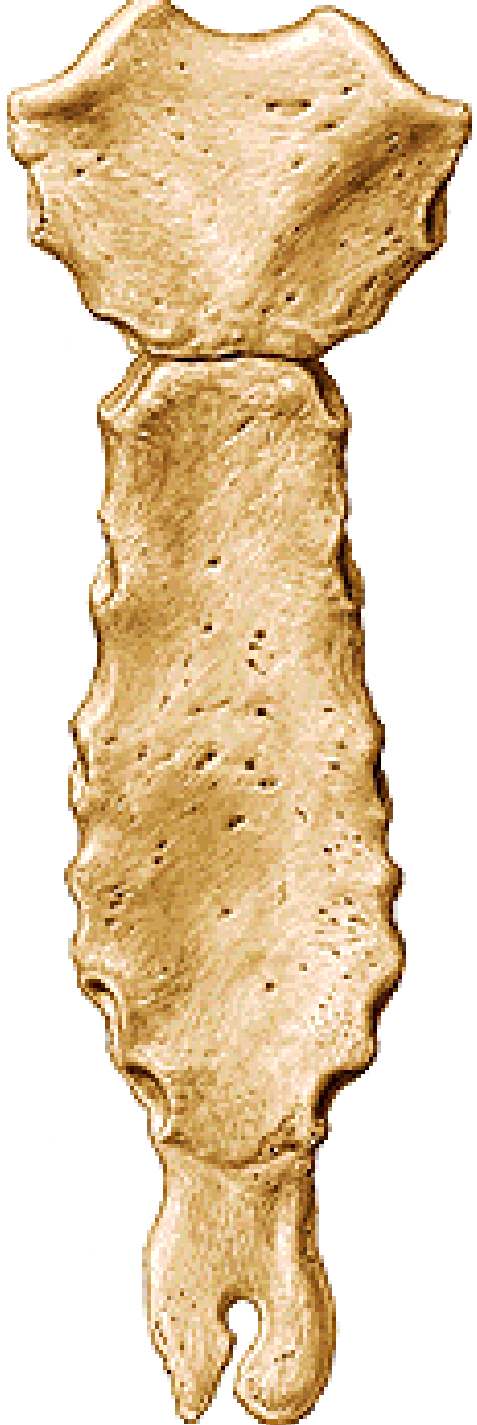
MANUBRIO

Incisura yugular
Incisura claviclar

CUERPO

AP. XIFOIDES

Escotaduras Costales



TIPOS DE COSTILLAS

Verdaderas 1-7

Falsas

8-12

Flotantes 11-12

PARTES

Cabeza

carillas articulares

cresta

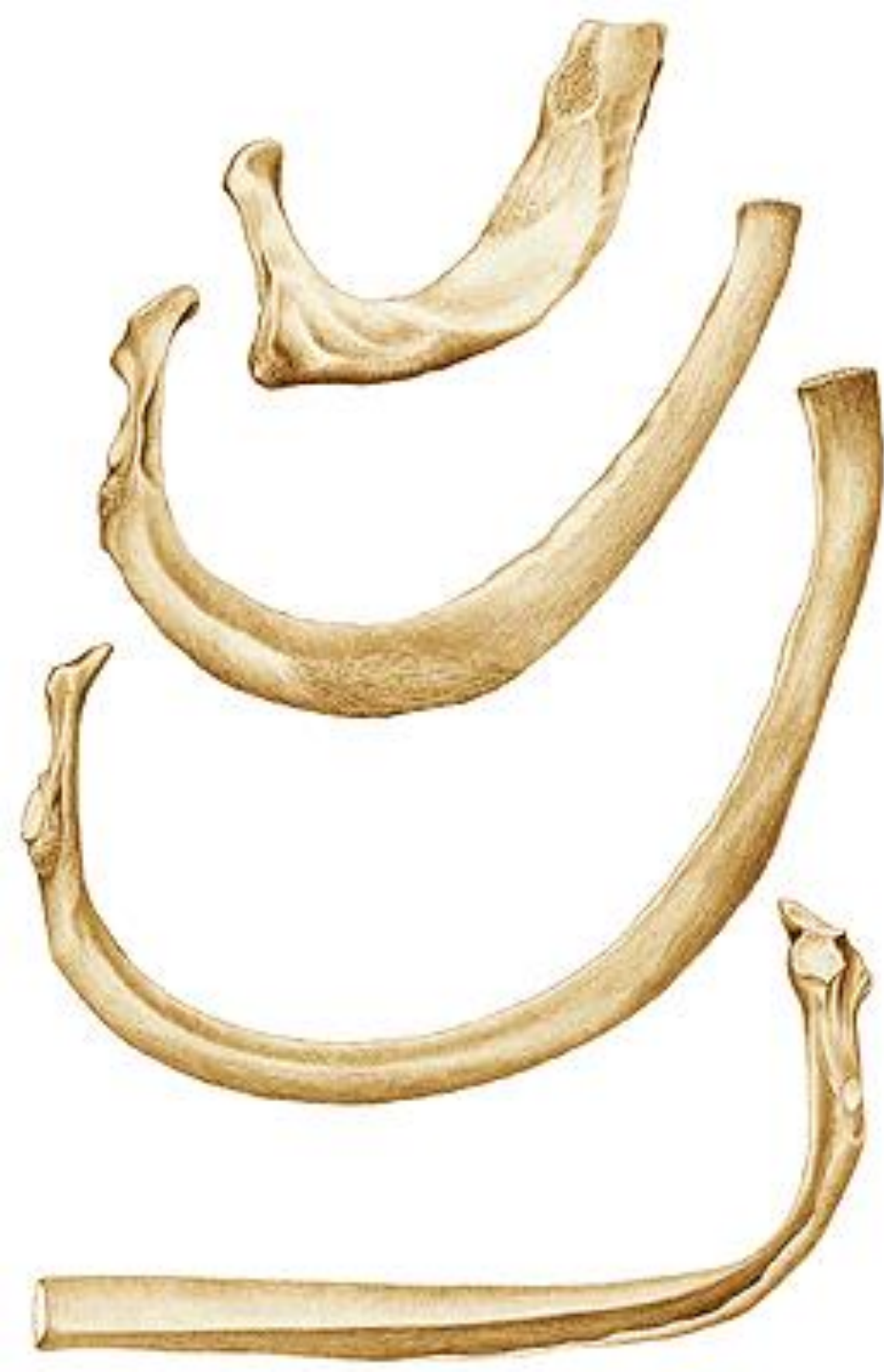Cuello

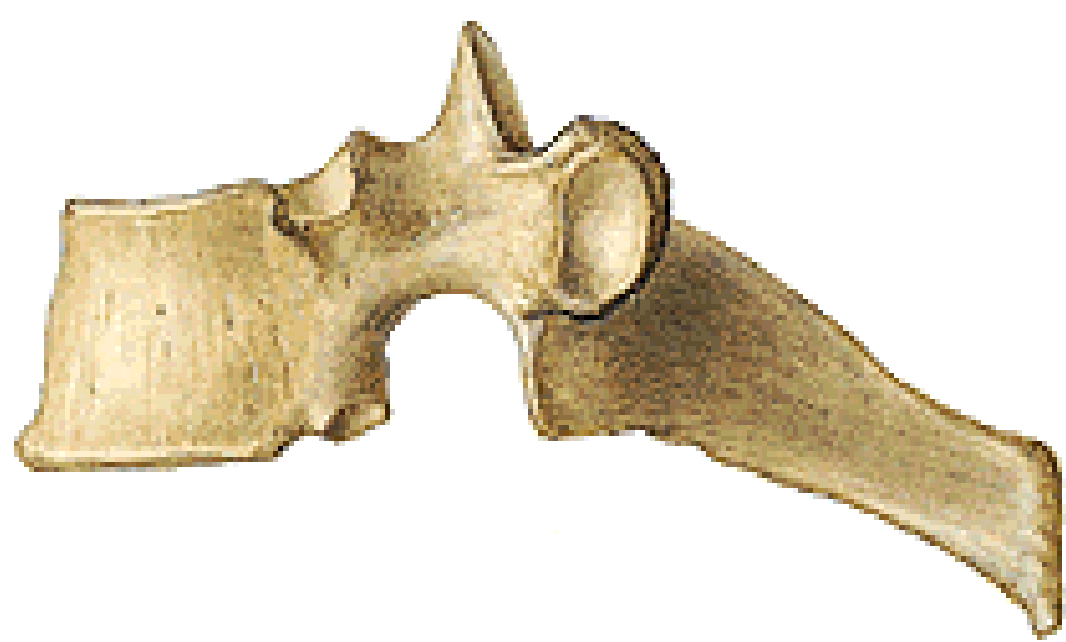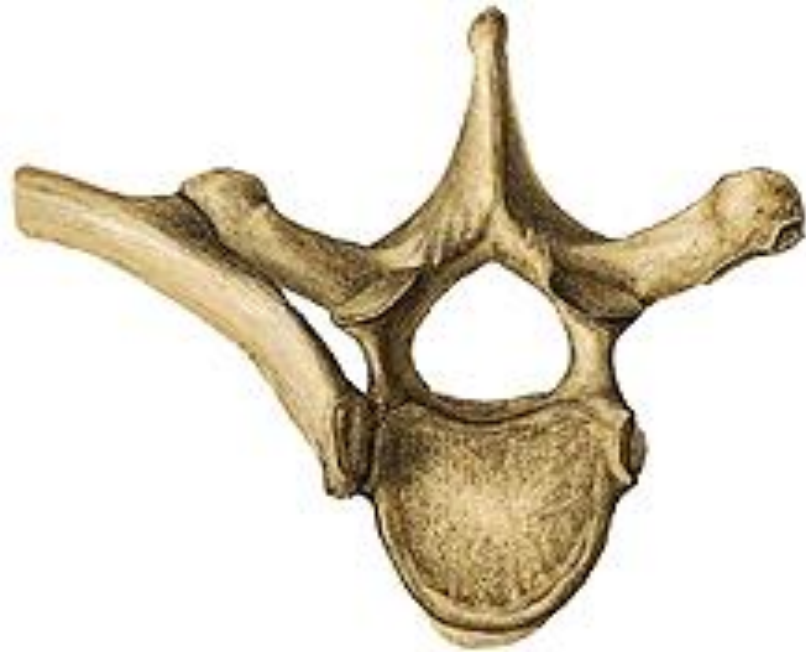tubérculo

carilla articular

Cuerpo

Ángulo Costal



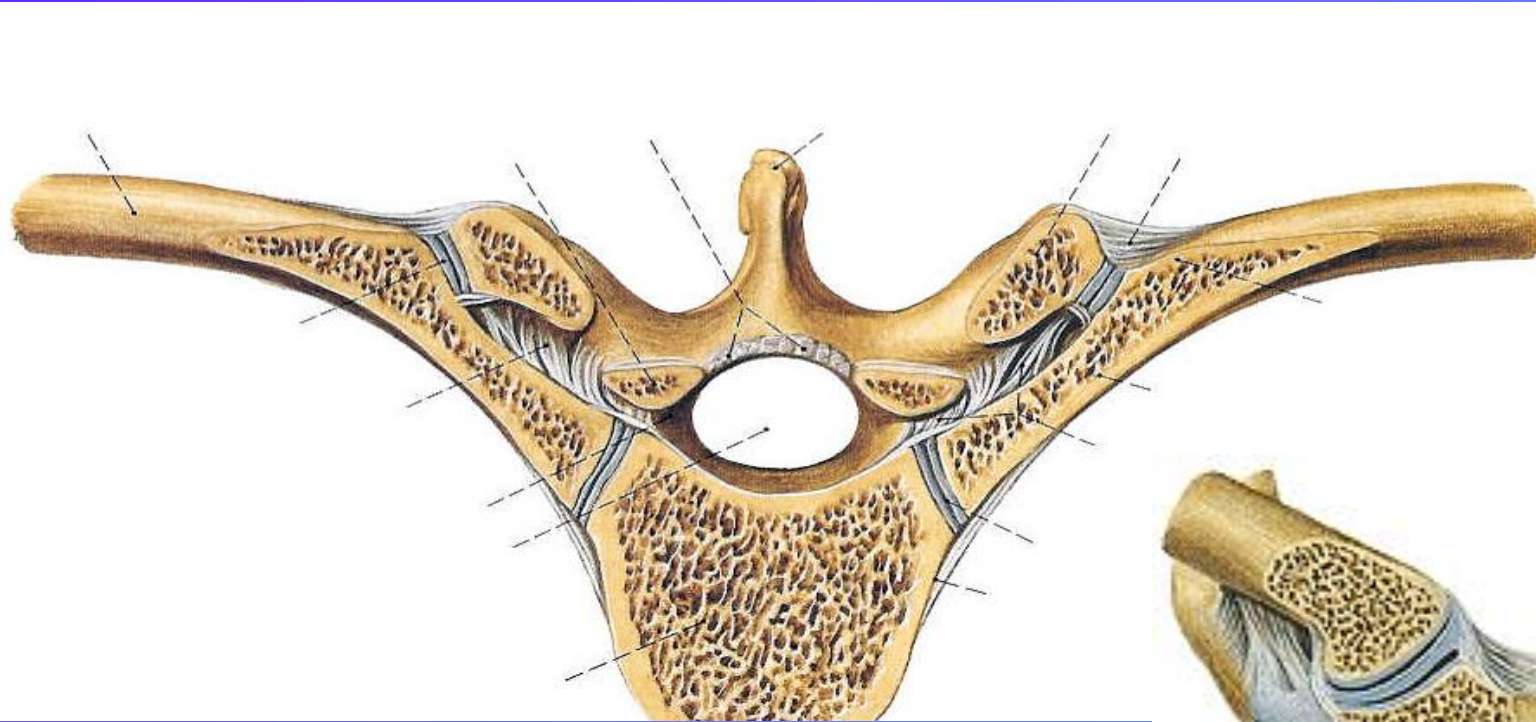


VERTEBRA TORÁCICA

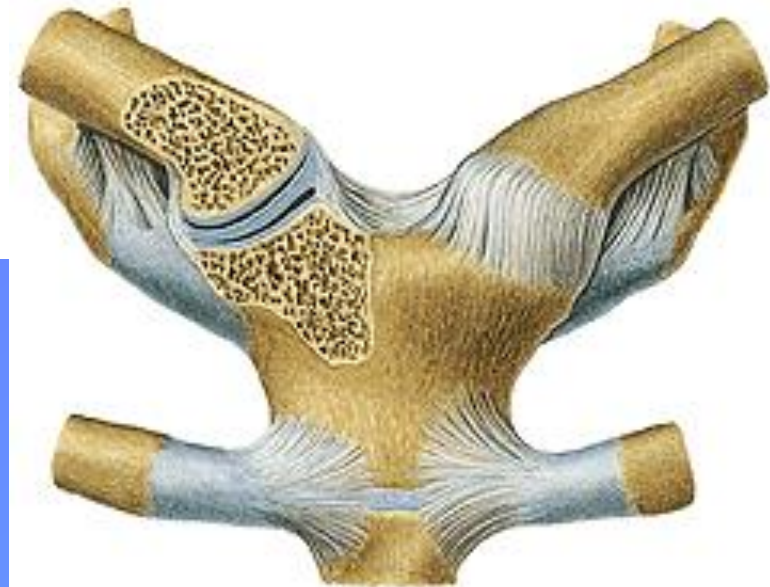
CARILLAS COSTALES: CUERPO Y AP. TRANSVERSA
AP. ESPINOSA LARGA Y VERTICAL

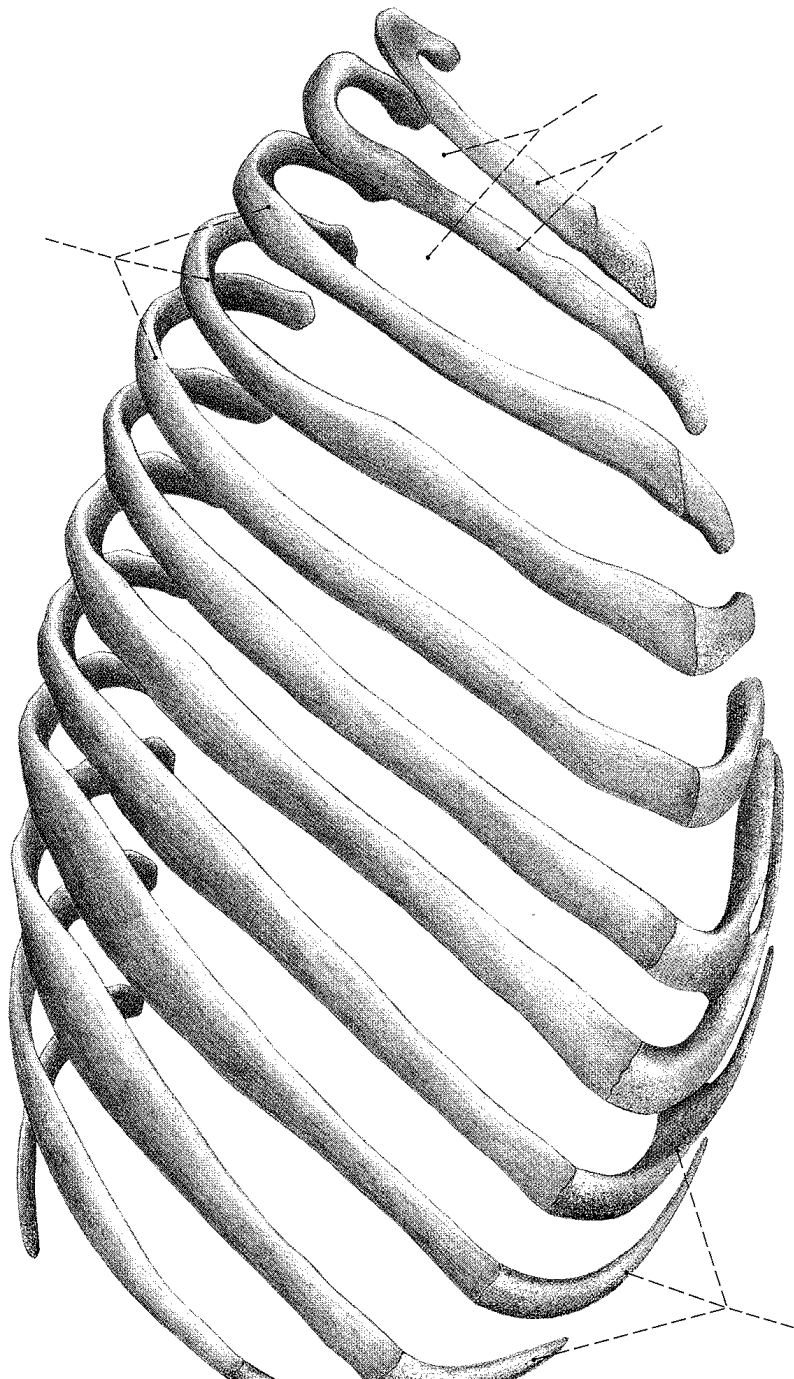
MOVIMIENTOS COSTALES

Articulaciones costovertebrales



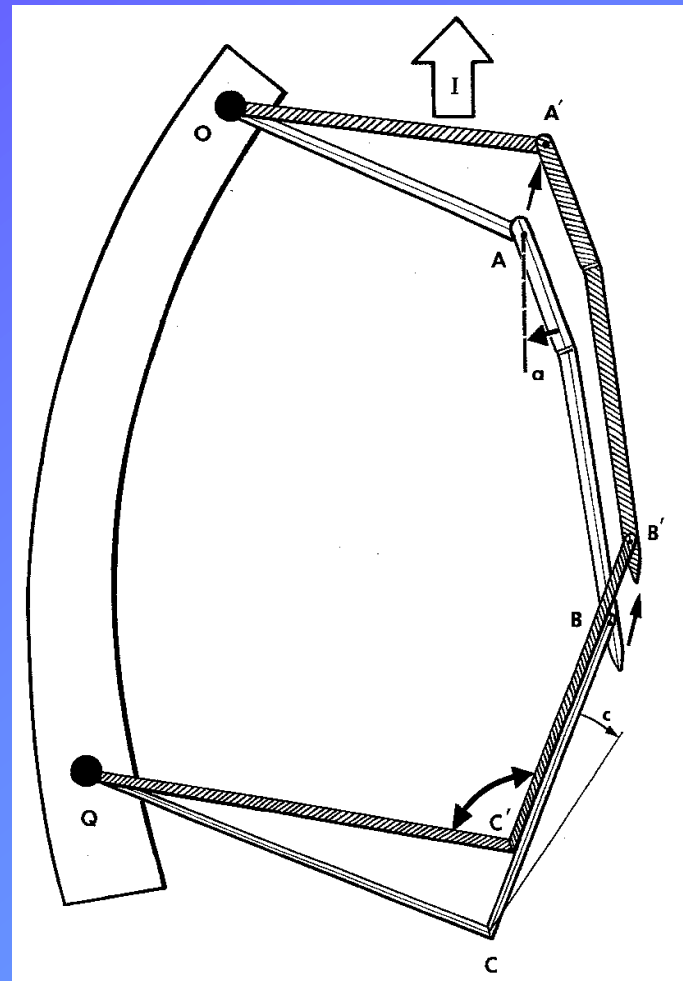
Articulaciones condroesternales

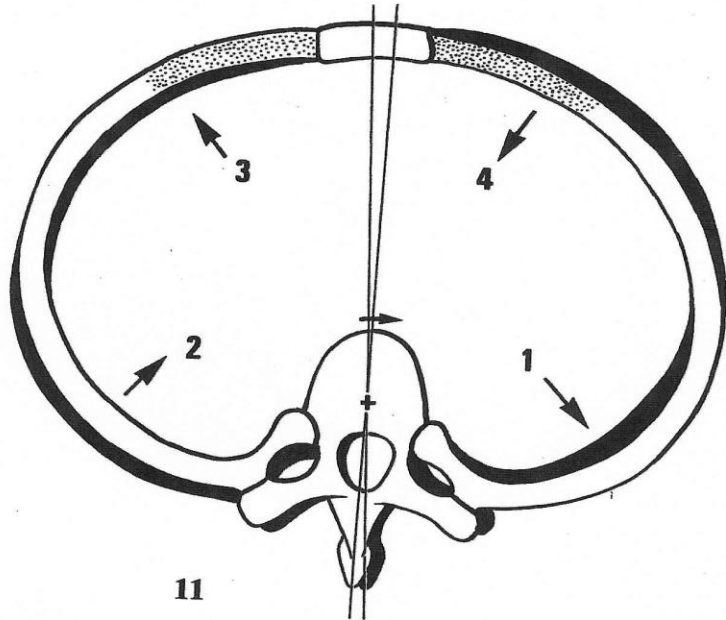




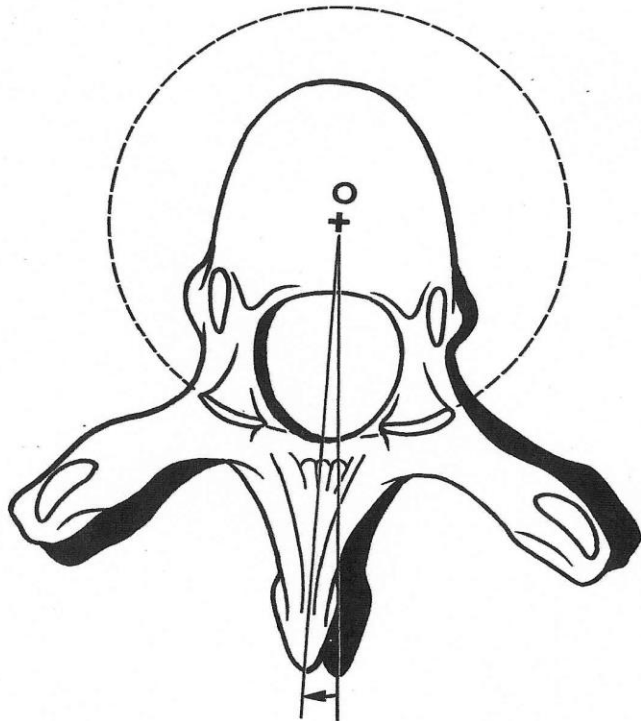
Articulaciones Costovertebrales
Articulaciones Condroesternales

Espacios Intercostales
Orificio Superior / Orificio Inferior

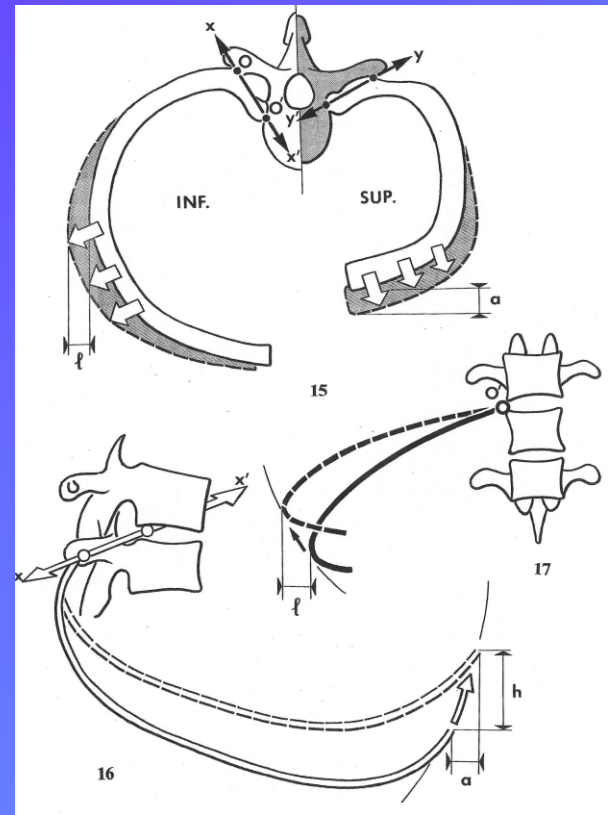




11



10



Espacios intercostales

AMPLITUD LATERAL
AMPLITUD AP